Head and neck

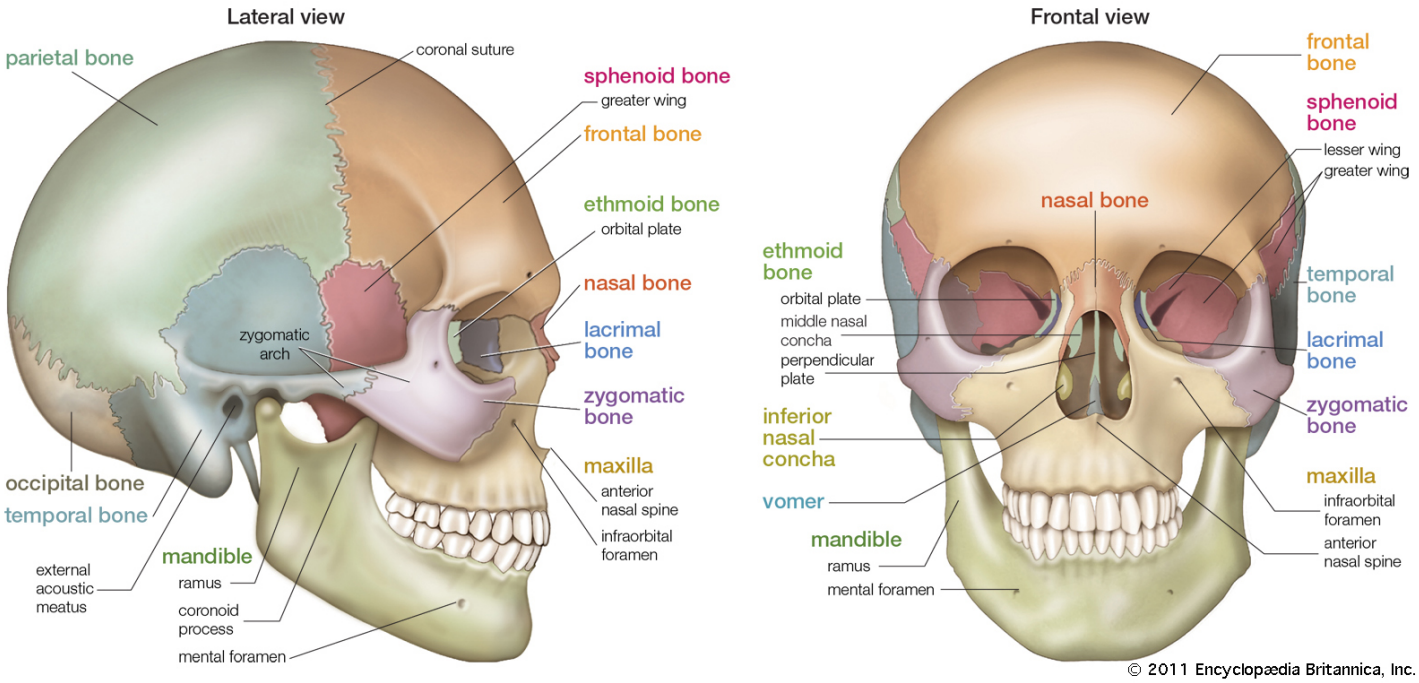

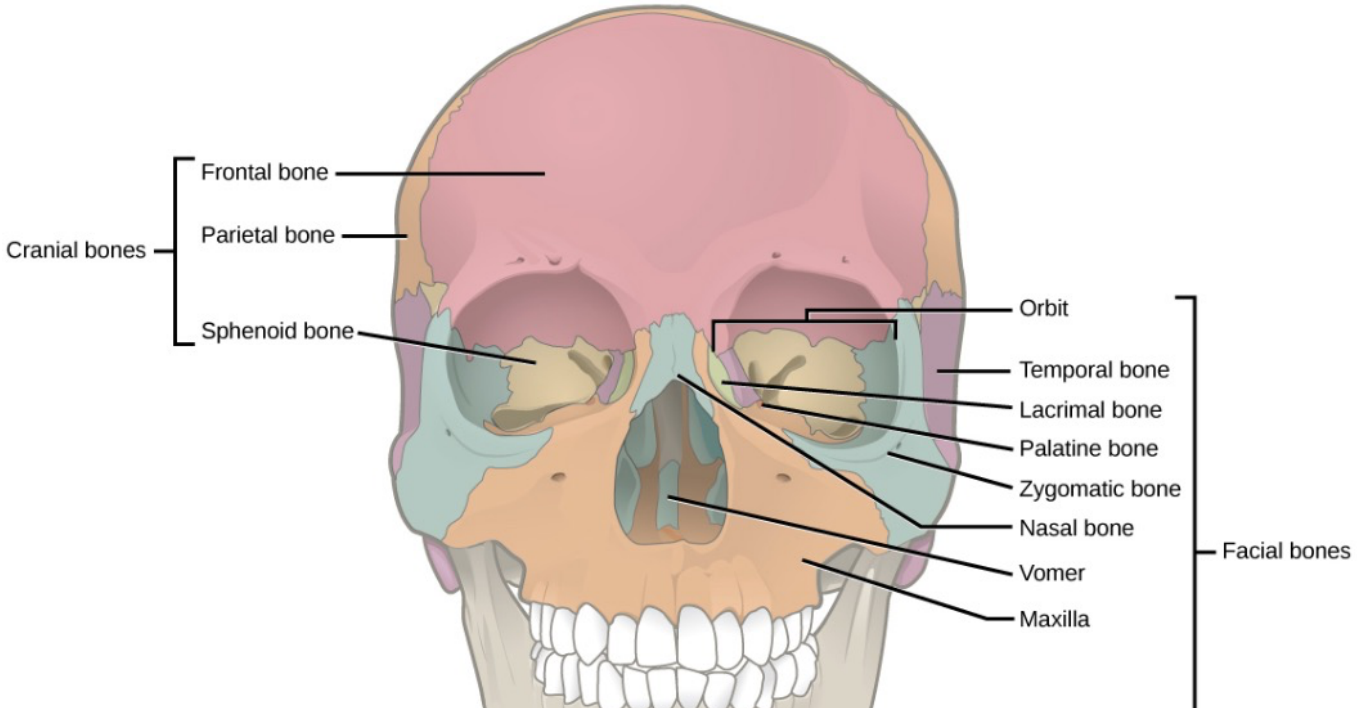

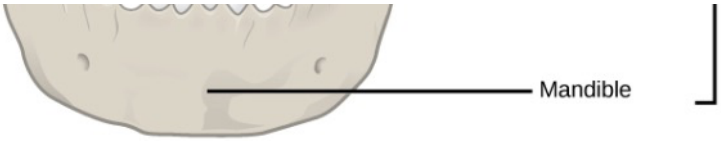

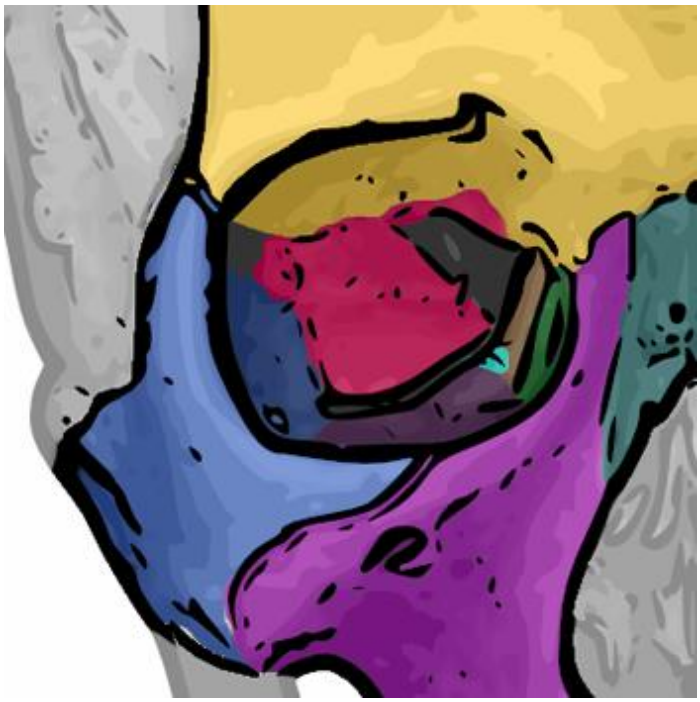

- Frontal bone - yellow
- Zygoma - blue
- Maxilla - purple
- Palatine - aqua
- Lacrimal bone - green
- Sphenoid - pink
- Ethmoid – brown

Temporal fossa

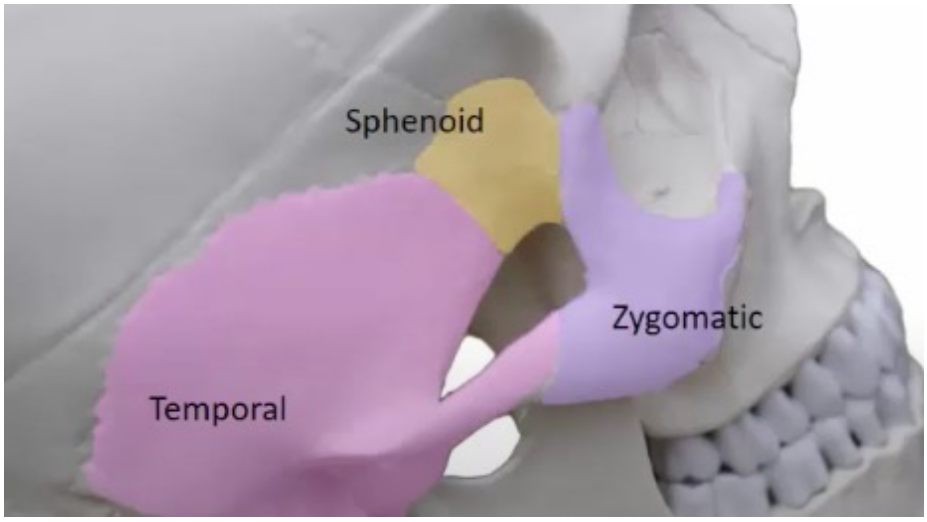

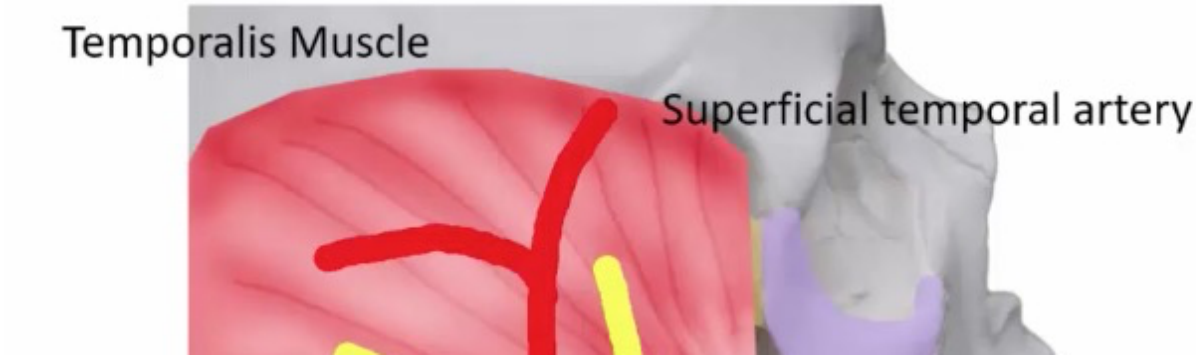

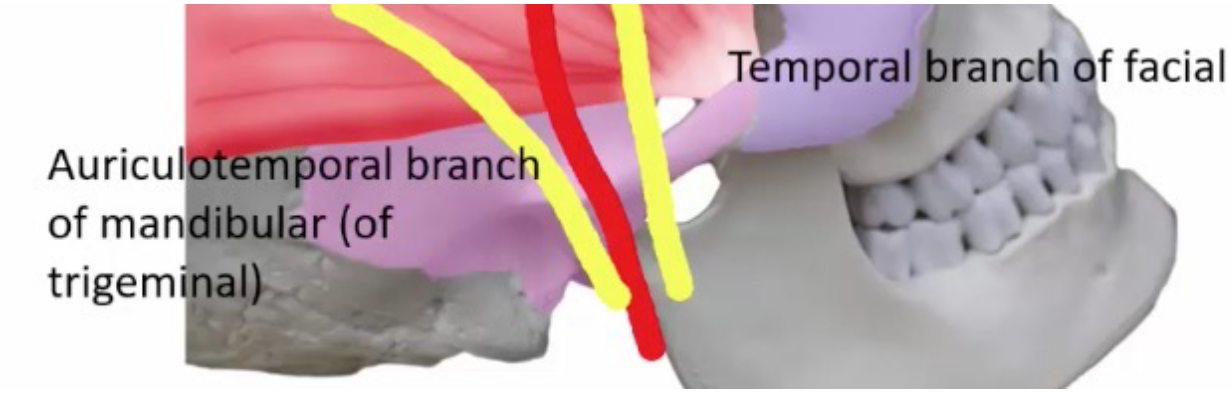

Running over temporal fossa:

- Temporalis muscle (inserts onto MANDIBLE, helps with mastication)
- Superficial temporal artery
- Auriculotemporal branch of trigeminal n (mandibular nerve)
- Temporal branch of facial n

Infratemporal fossa

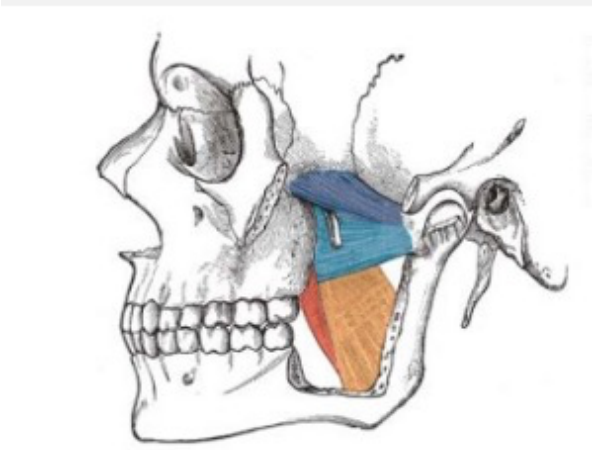

- Pterygoids, ptegrygoid plexus and mandibular branch of CN V (enters from foramen oval

PARANASAL SINUSES

- Maxillary and ethmoidal present at birth
- Frontal - last to develop, finished around late teenage years

---

TMJ ligaments

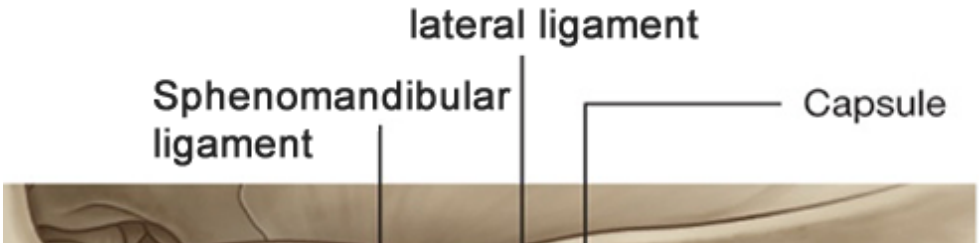

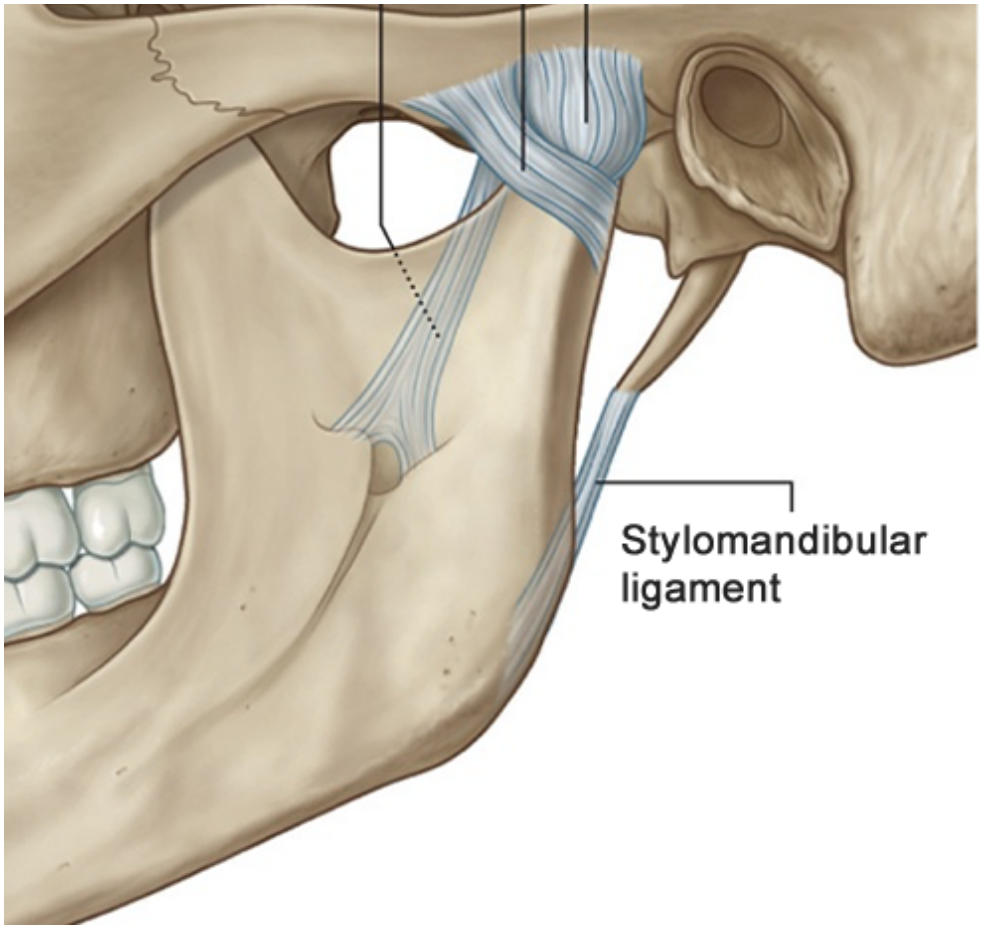

Muscles:

- Temporalis - elevation and retraction of the mandible
- Masseter - elevation
- Medial pterygoid - elevation and lateral movement
- Lateral pterygoid - protrusion and lateral movement
- Diagastric - open mouth
  - 

Facial nerve

- Motor - muscles of face
- Sensory - anterior 2/3 tongue (TASTE *not* sensation, which is the trigeminal n (lingual)
- Parasympathetic - glands (except parotid)

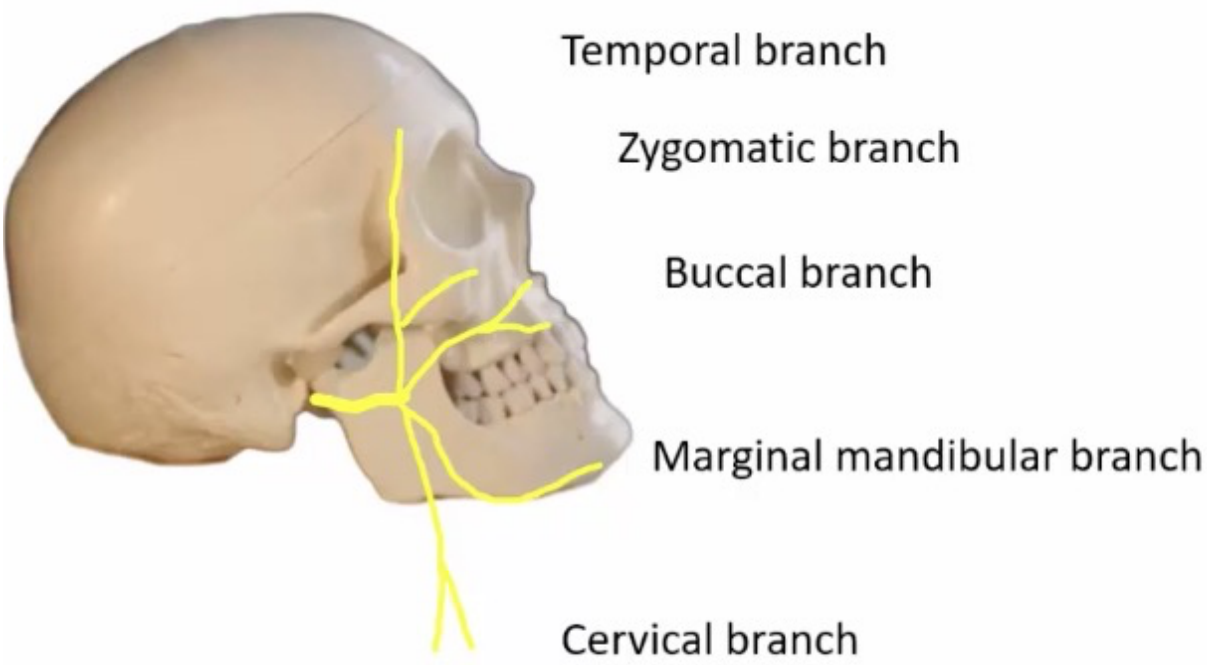

Motor = extracranial portion of CN VII. Exits at stylomastoid foramen (between styloid and mastoid)

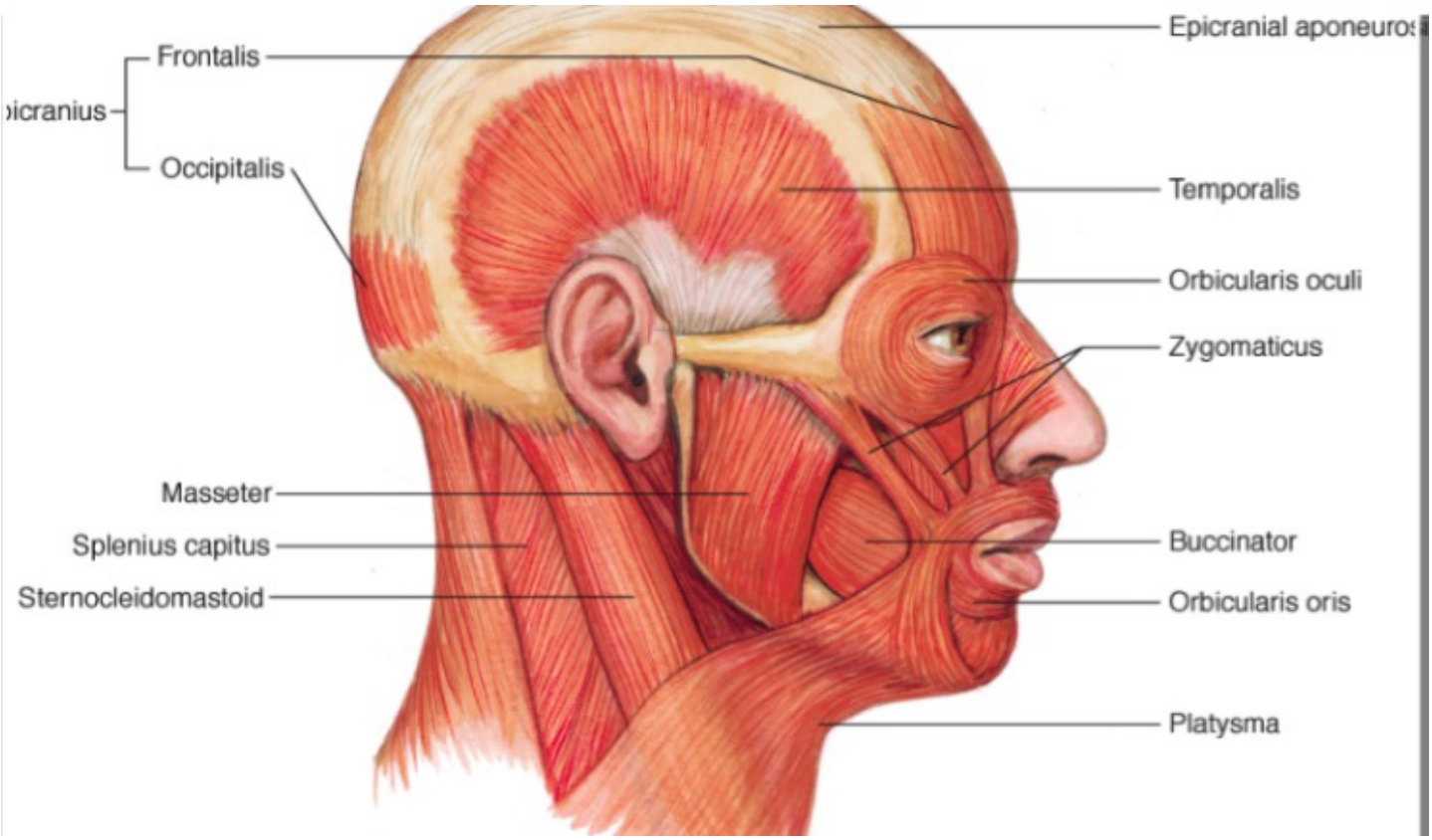

1. **Temp oral**
   - Frontalis
   - Orbicularis oculi (sup part)
2. **Zygomatic**
   - Orbicularis oculi (inf part)
3. **Buccal branch**
   - Orbicularis oris - *purses the lips*
   - Zygomaticus
   - Buccinator - *sucks the cheeks in against teeth, stops food pouching in cheeks*

4. **Marginal mandibular**
    - Mentalis
5. **Cervical**
    - Platysma

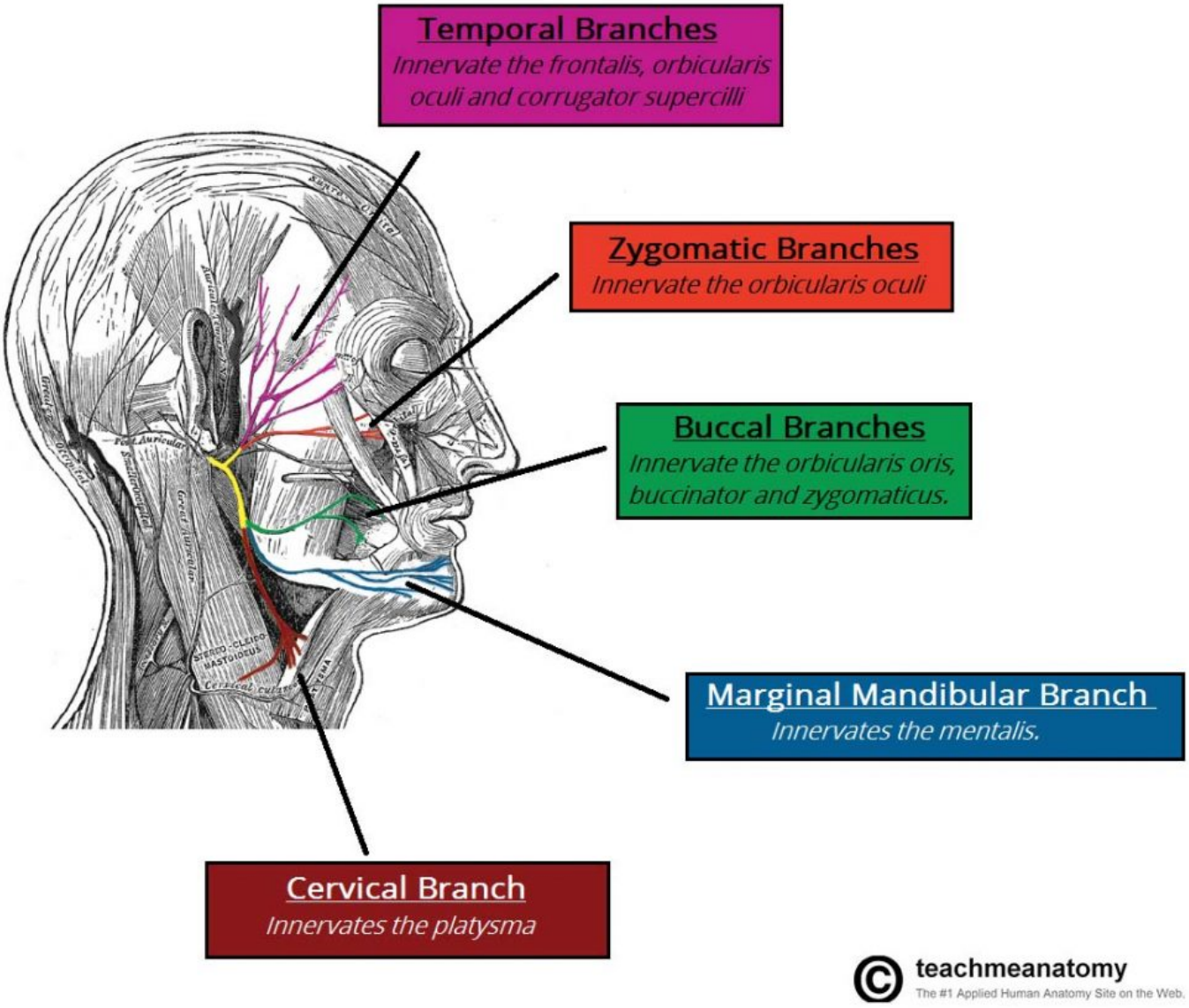

TRIGEMINAL

- Sensory of face
- Motor of mastication
- Afferent of corneal reflex (ophthalmic branch of trigeminal n)

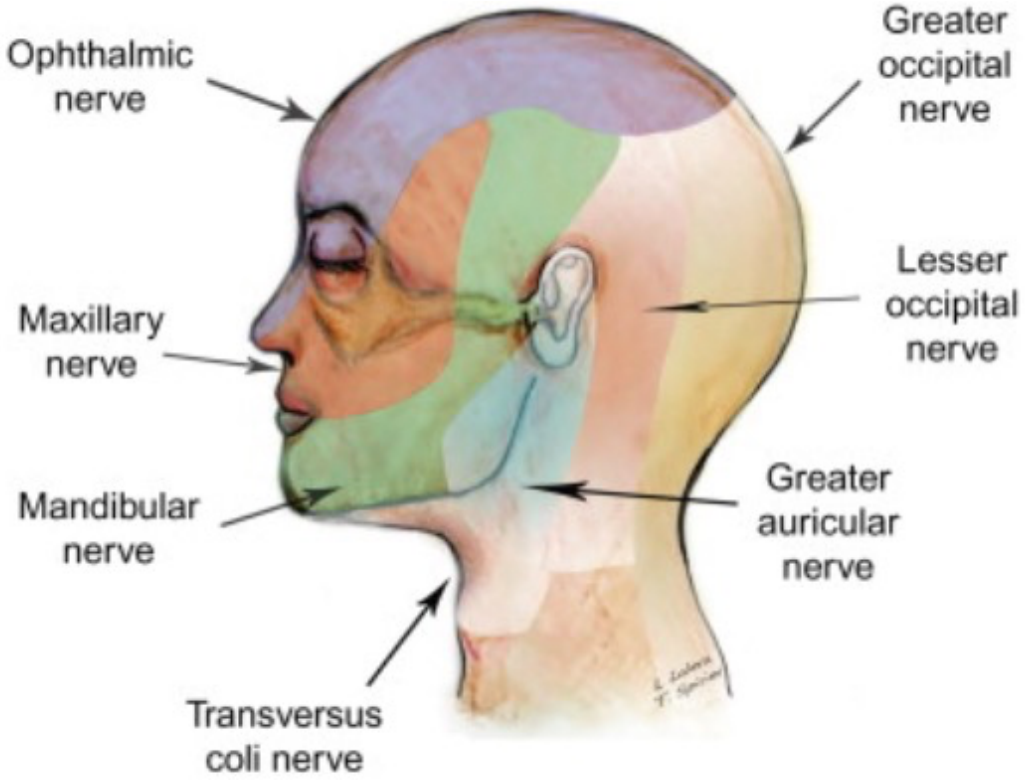
Ophthalmic nerve
Greater occipital nerve
Lesser occipital nerve
Maxillary nerve
Mandibular nerve
Greater auricular nerve
Transversus coli nerve

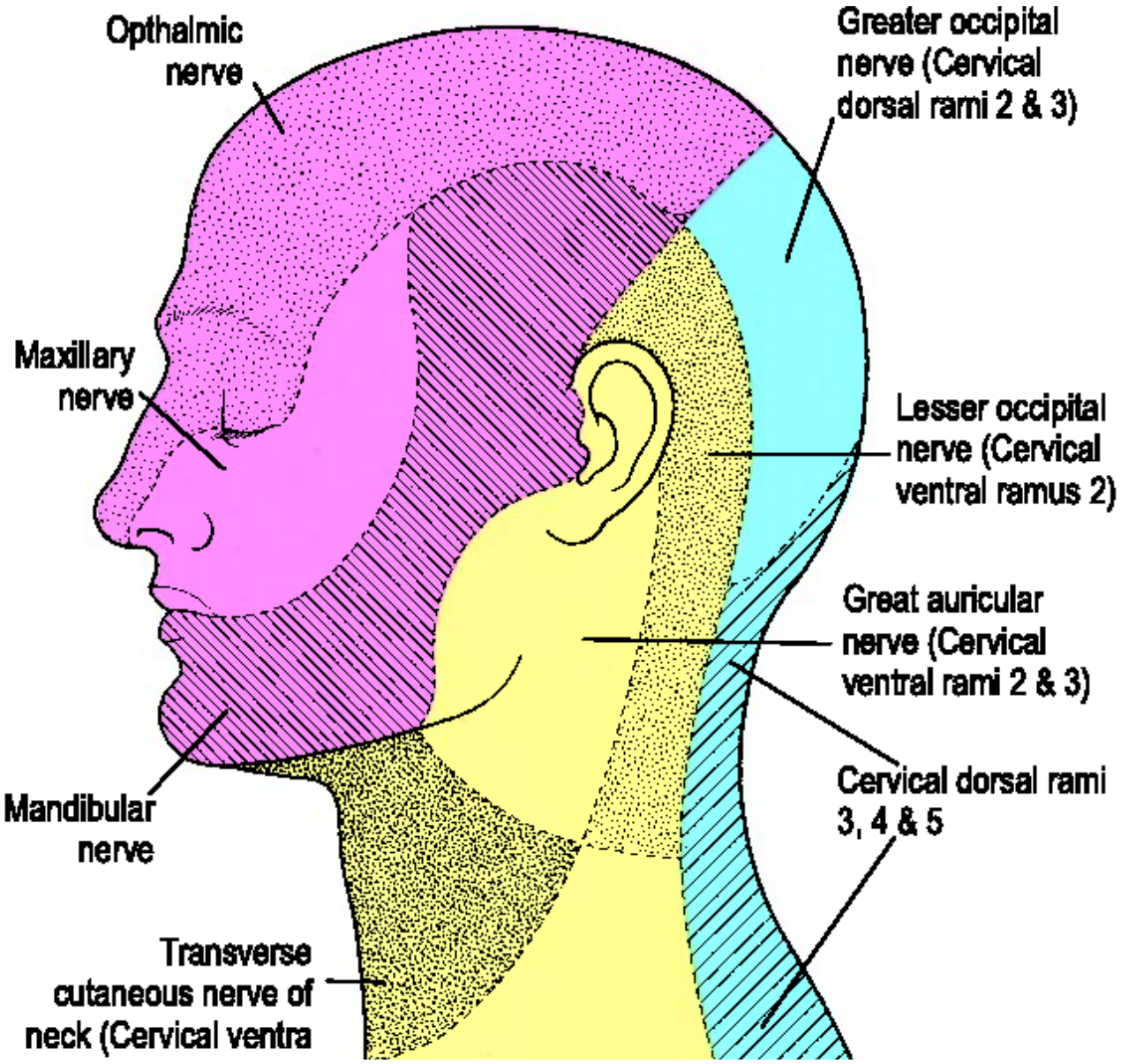
Opthalmic nerve
Greater occipital nerve (Cervical dorsal rami 2 & 3)
Maxillary nerve
Lesser occipital nerve (Cervical ventral ramus 2)
Great auricular nerve (Cervical ventral rami 2 & 3)
Cervical dorsal rami 3, 4 & 5
Mandibular nerve
Transverse cutaneous nerve of neck (Cervical ventra

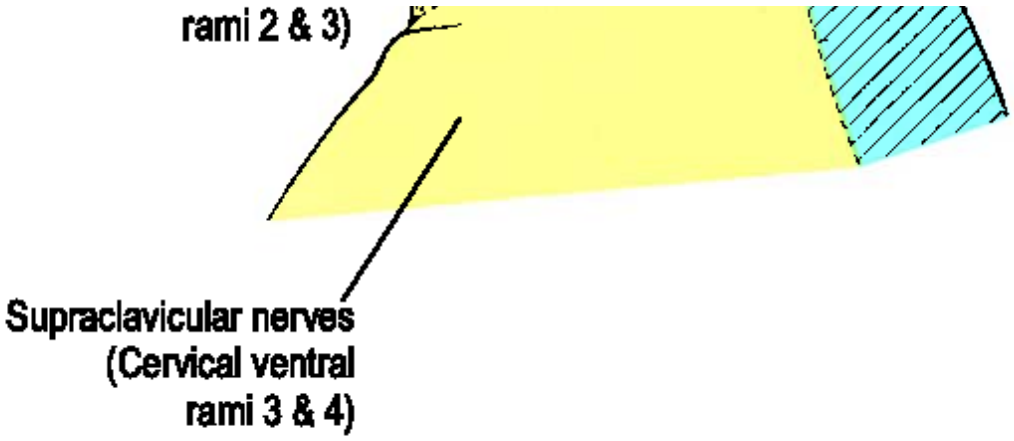

Figure 5. The cutaneous nerve supply of the face, scalp and

SENSATION of head

- **Trigeminal nerve:**
  - V1 (ophthalmic) - to angle of eye (lateral canthus)
  - V2 (maxillary) - to angle of mouth
  - V3 (mandibular) - to angle of mandible
- **C2 and C3**
  - Greater occipital nerves
  - Lesser occipital nerves
  - Great auricular nerve

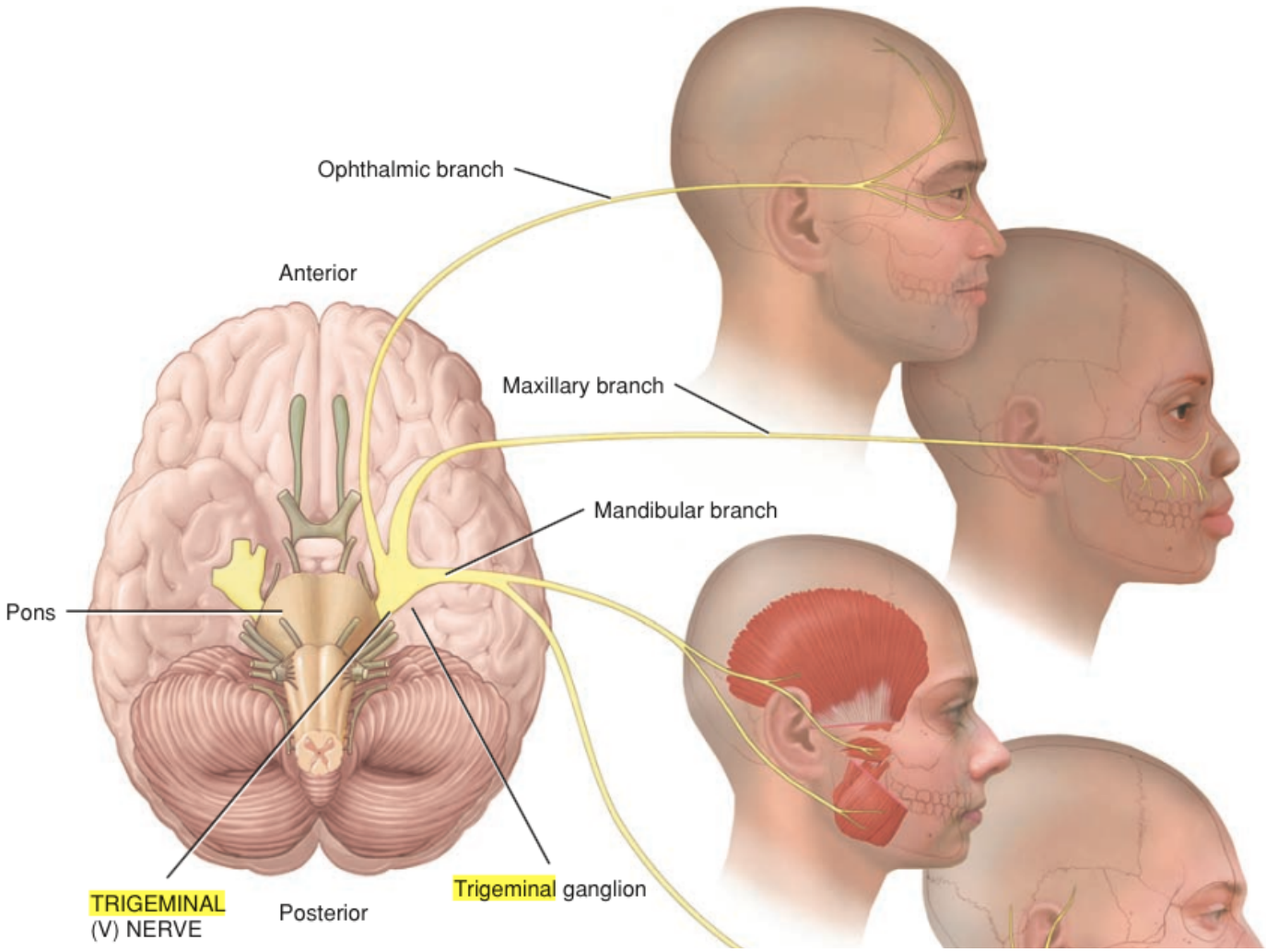

- **Sensory**
  - Opthalmic V1 (*Corneal reflex (ophthalmic v = afferent // facial nerve = efferent)*
    1. Supraorbital
    2. Supratrochlear
    3. Infratrochlear
    4. External nasal / anterior ethmoidal
    5. Lacrimal
  - Maxillary V2
    1. Zygomaticotemporal
    2. Zygomaticofacial
    3. Infra-orbital
  - Mandibular V3
    1. Auriculotemporal
    2. Buccal
    3. Mental
- **Motor (Mandibular)**
  - Temporalis
    - Temporal fossa—>coronoid process, elevates mandible
  - Masseter
    - Zygomatic arch—>mandible, elevates mandible
  - Medial pterygoids - *lateral jaw movement, chewing*
  - Lateral pterygoids - *protrudes jaw, helps open jaw*
    - 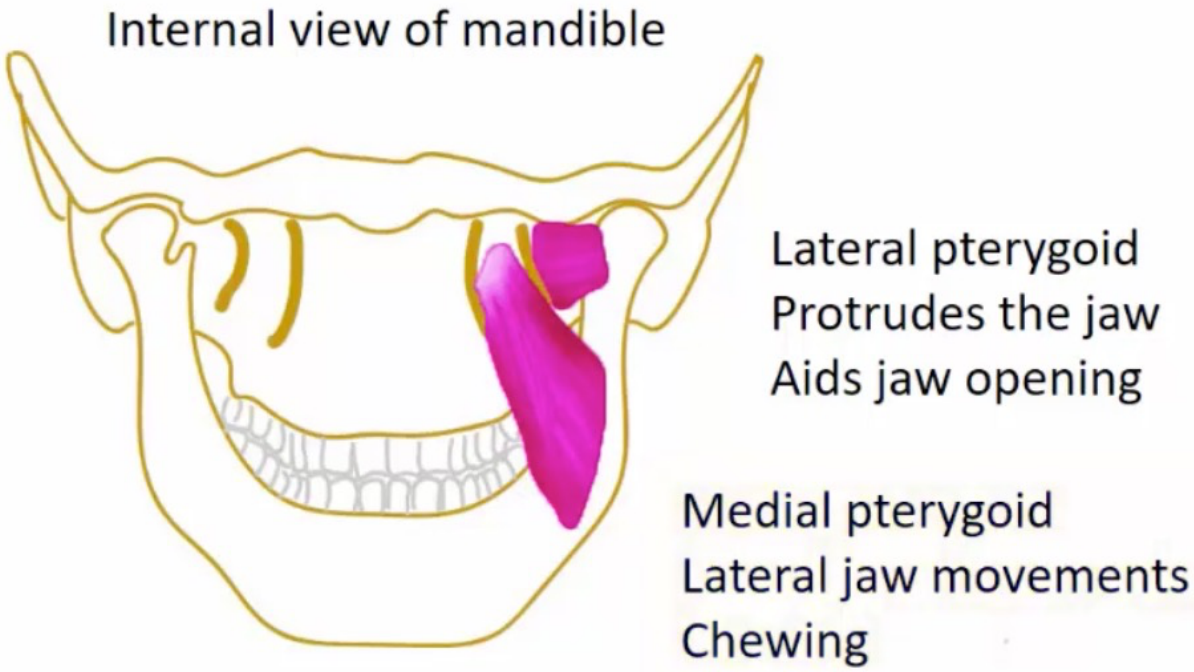

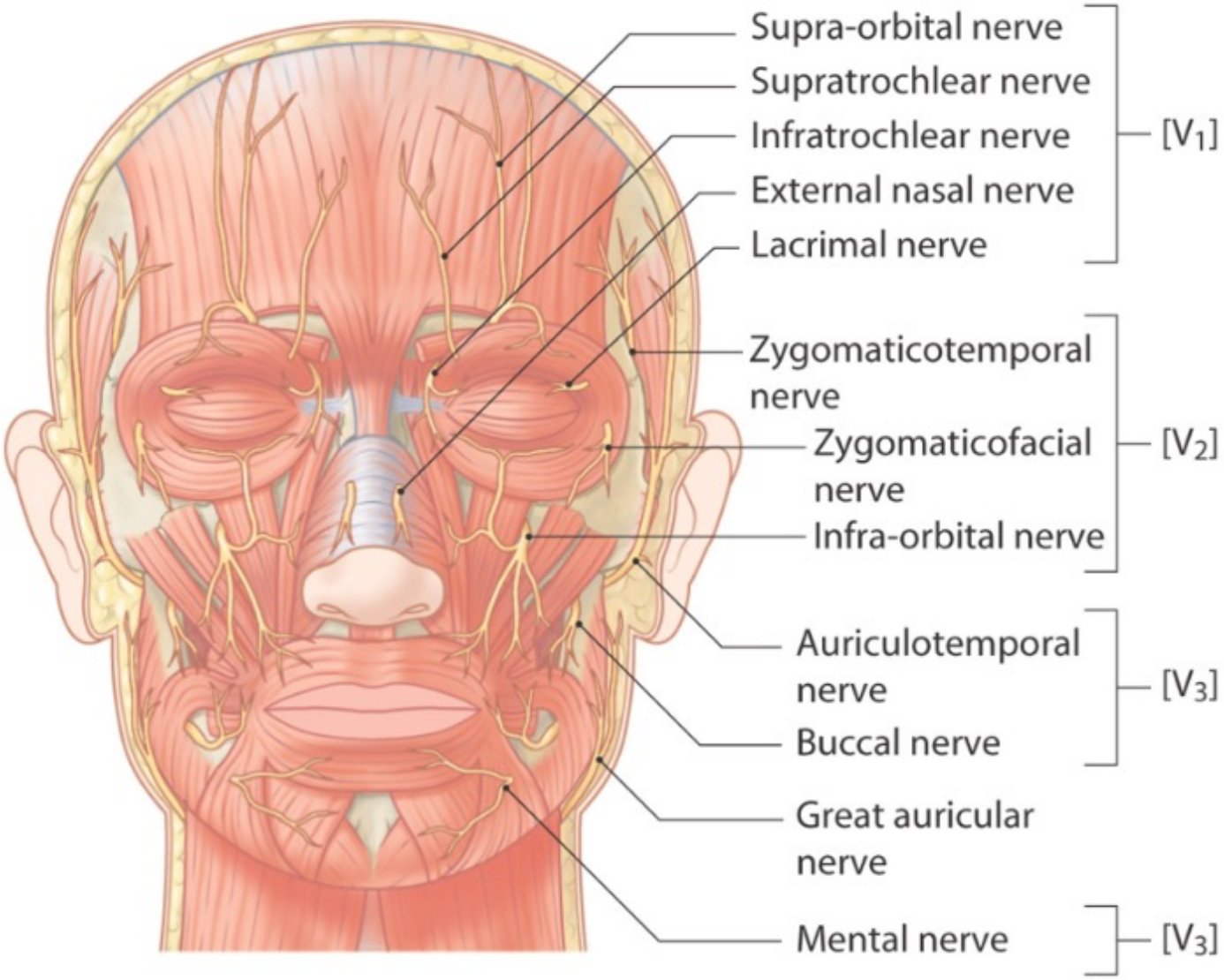

Mandibular nerve

- **Why unique?**
  - Its the only branch of the trigeminal nerve that has motor innervation:
  - - Masseter, temporalis, lateral and medial pterygoids
- **Sensory function:**
  1. Skin
     - Auriculotemporal branch
       - Inf root —> branches from CN IX to innervate parotid gland
       - Sup root —> sensation temporal, ext ear, and Tympanic membrane
     - Buccal branch
       - Buccal membranes of the mouth i.e. cheeks
     - Lingual branch - anterior 2/3 tongue
     - Inferior alveolar - --> emerges through mental foramen in mandible to become the *mental nerve*
  2. Anterior 2/3 tongue (sensation *NOT* taste) - **lingual branch**
  3. Inferior row of teeth and gingiva
- **Autonomic**
  - Mandibular nerve does not have its own autonomic nucleus, but takes on nerves from:
    - 1. Facial nerve --> corda tympani --> joins lingual nerve --> innervates submandibular and sublingual glands

sublingual glands

- 2. Glossopharyngeal nerve --> auriculotemporal nerve --> parotid gland

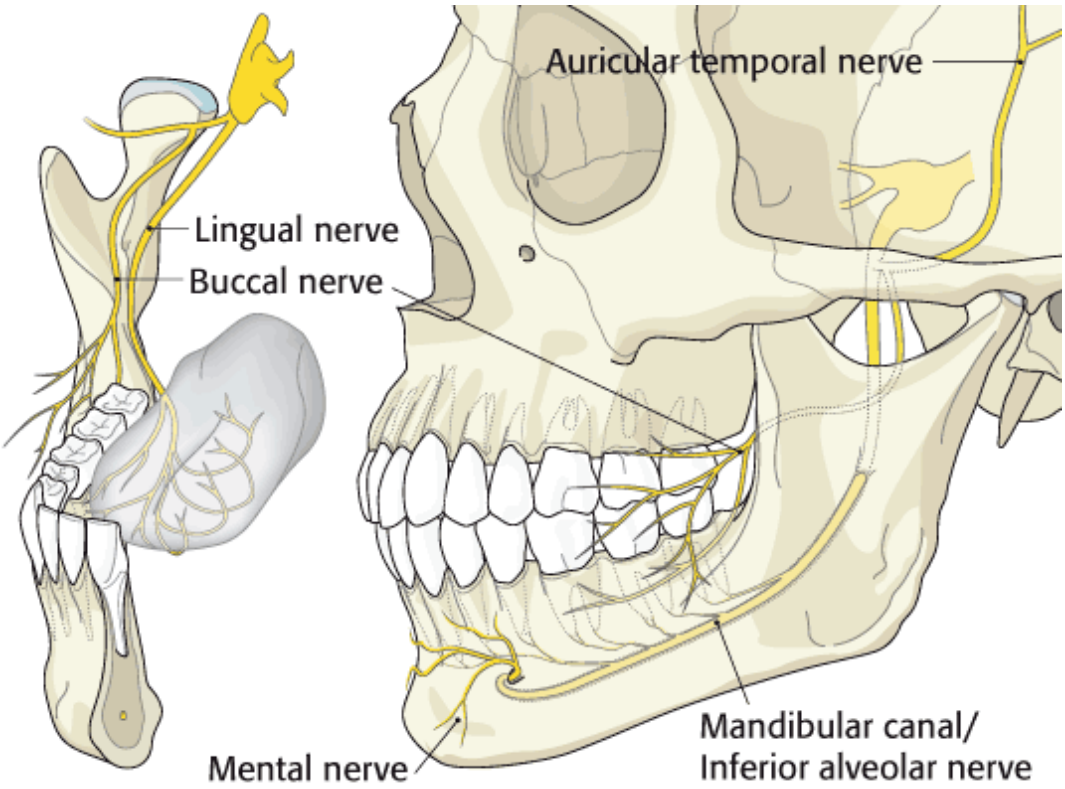

Blood supply

Mainly need to know:

- facial artery and temporal artery
-

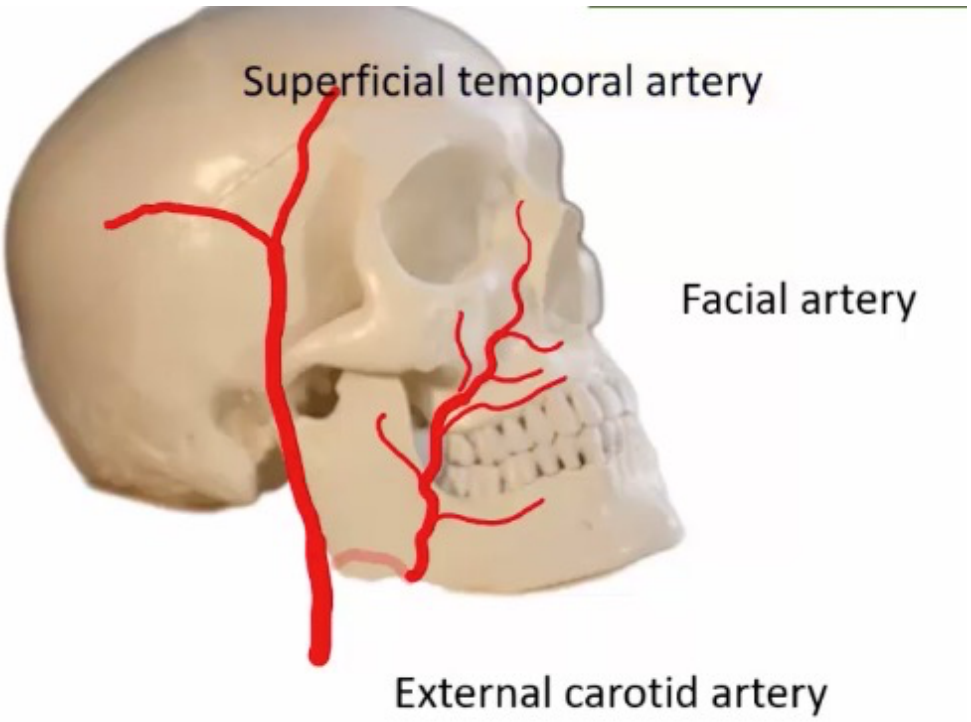

VENOUS

Cavernous sinus

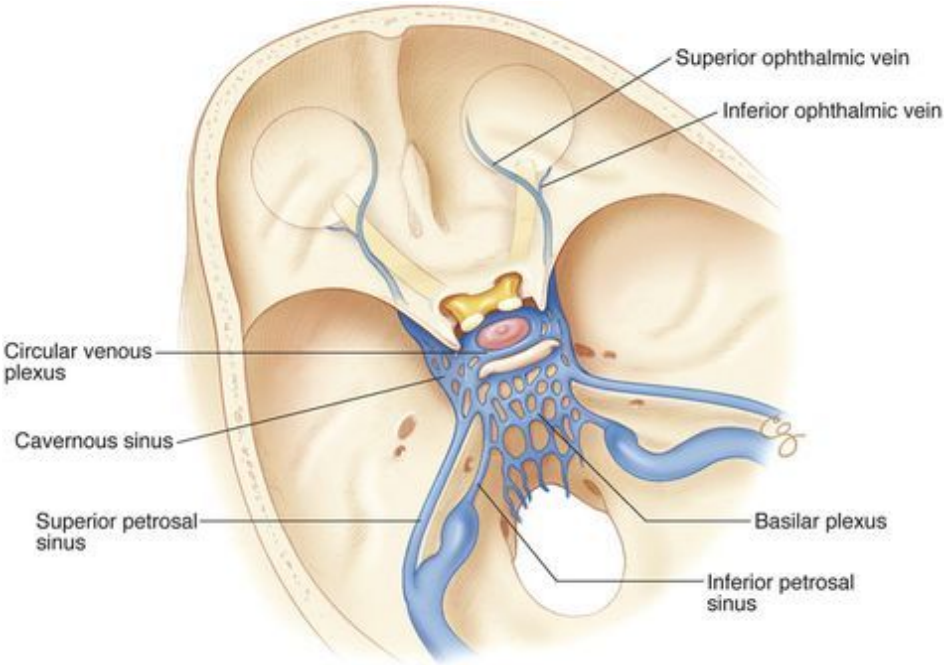

- communication between facial vein and cavernous sinus
  - 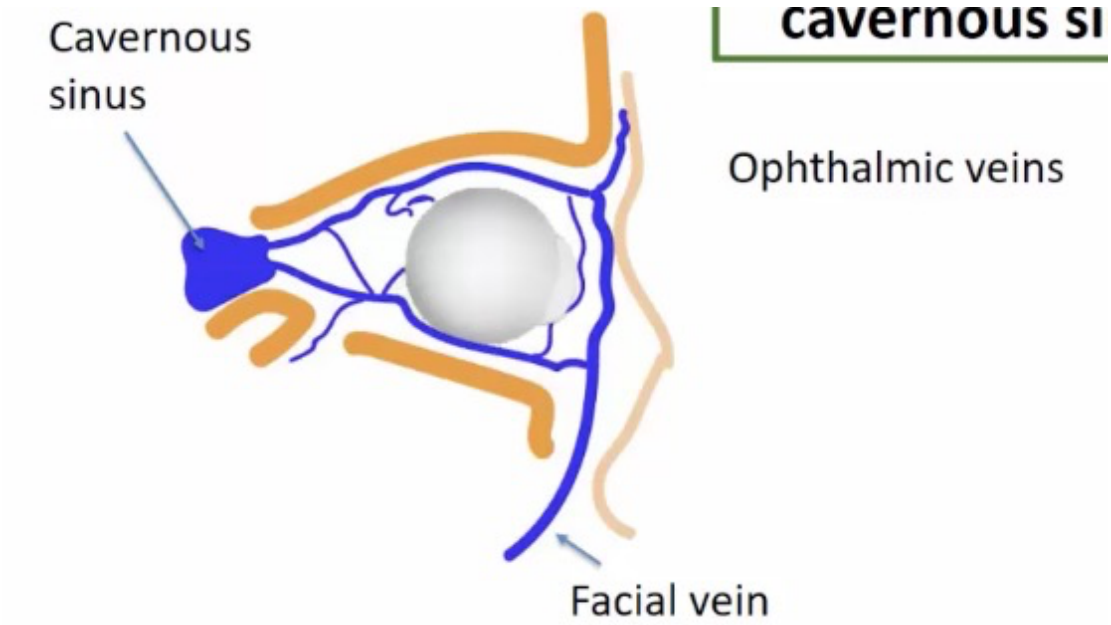

  - Infection/thrombosis in area of face can spread back into cavernous sinus

Pterygoid venous plexus

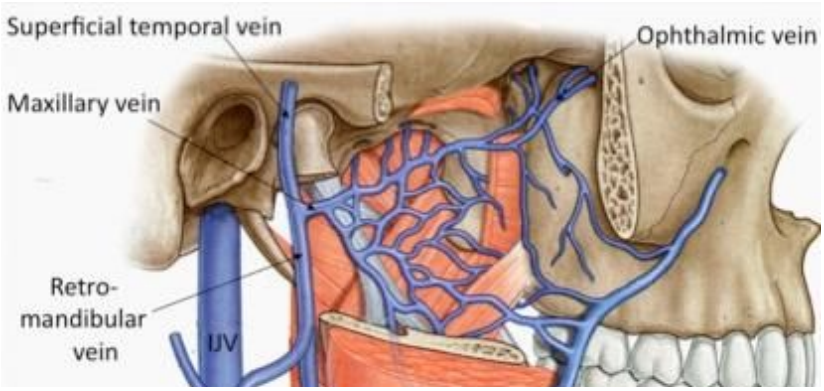

- Drains via maxillary vein —> retromandibular vein —> ext jugular
- Connections with inf ophthalmic veins and cavernous sinus

Nose

External

- Sensory:
  - Trigeminal
    - V1 —> external nasal n
    - V2 —> infra-orbital n
- Vasculature
  - Ext carotid —> facial a
  - Facial v

Nasal cavity

- 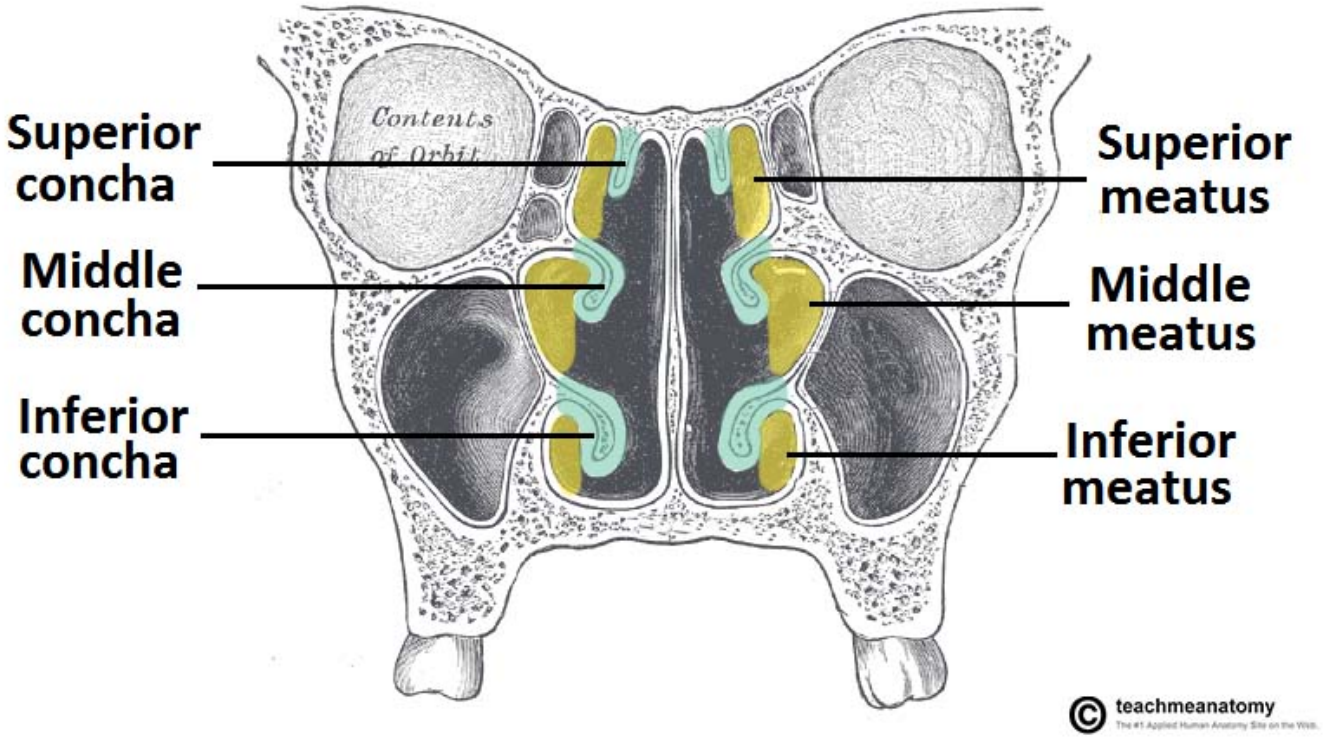

  - 3 Turbinates/conchae (inf, mid, sup) - *these are BONES that are lateral to the nasal cavity and curl medially and downward to create the meatuses*
  - 4 Meatuses (inf, mid, sup, sphene-ethmoidal recess)

- Openings into nasal cavity
  - 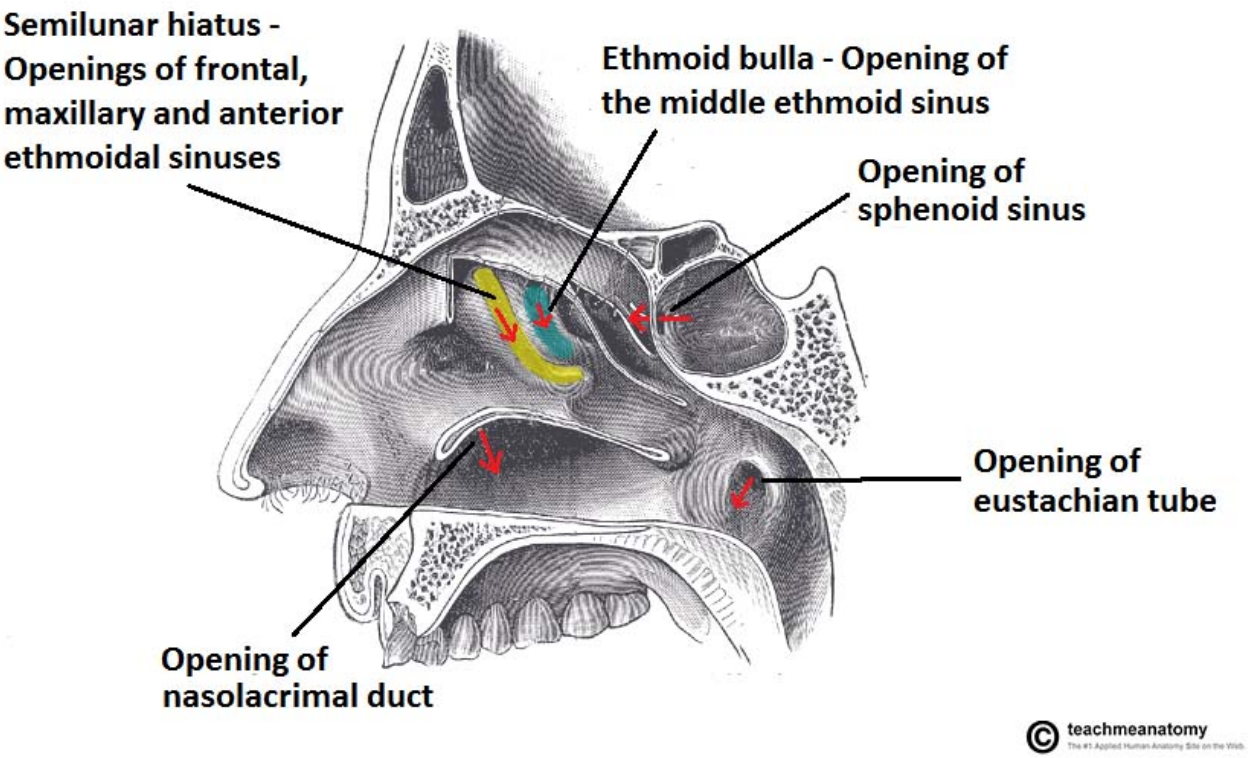

  - All these openings can be routes to and from infection - e.g. URTI —> middle ear inf
    1. Sphenoid sinus —> sphenoethmoidal recess - posterior roof of nasal cavity
    2. Frontal, maxillary, and ethmoidal sinuses —> into middle meatus
    3. Eustachian tubes
    4. Naso-lacrimal duct —> inferior meatus
       - *Drains excess tears. Allergies —> runny nose*
       - 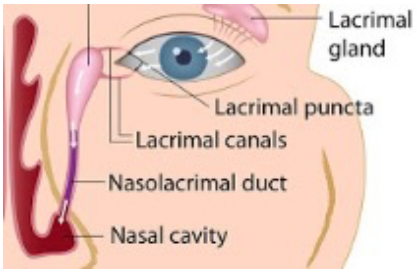

  - Blood supply
    - Int carotid —> ophthalmic arteries —>
      1. Ant ethmoidal a
      2. Post ethmoidal a
    - Ext carotid —>
      1. Sphenopalatine/nasopalatine a (maxillary a.)
      2. Greater palatine a (maxillary a.)
      3. Superior labial a (facial a.)
      4. Lateral nasal a
    - **Nasal Septal Vascular supply**
      - *These arteries anastamose with each other - MOST CONVERGE INTO LITTLE'S AREA*
      - ***LITTLES AREA ARTERIES***
        - Anterior ethmoidal
        - Sphenopalatine

        - Superior labial
        - Greater palatine
    - 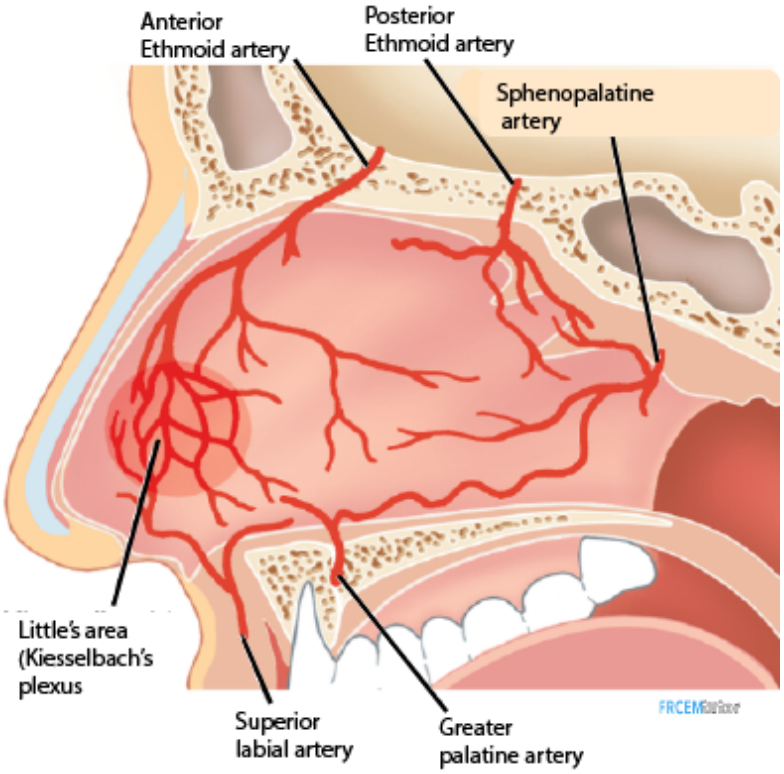

    - **Nasal lateral walls vascular supply**
        - 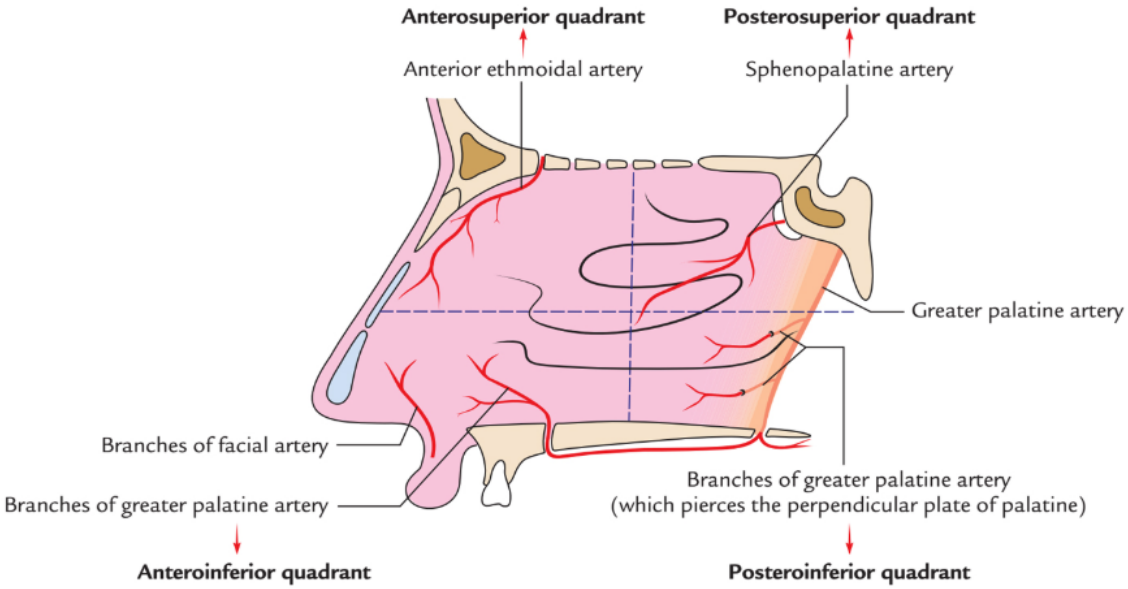

    - *Veins follow the arteries. Drain into*
        - Pterygoid plexus
        - Facial veins
        - Cavernous sinus
- <u>Innervation</u>
    - Special = olfactory nerve
        - Olfactory bulb (part of brain) sits on top of the cribriform plate
    - Sensory
        - Trigeminal n
            - —> Ophthalmic branch —> nasociliary nerve
            - —> Maxillary branch —> nasopalatine nerve

        - —> Maxillary branch —> nasopalatine nerve
    - 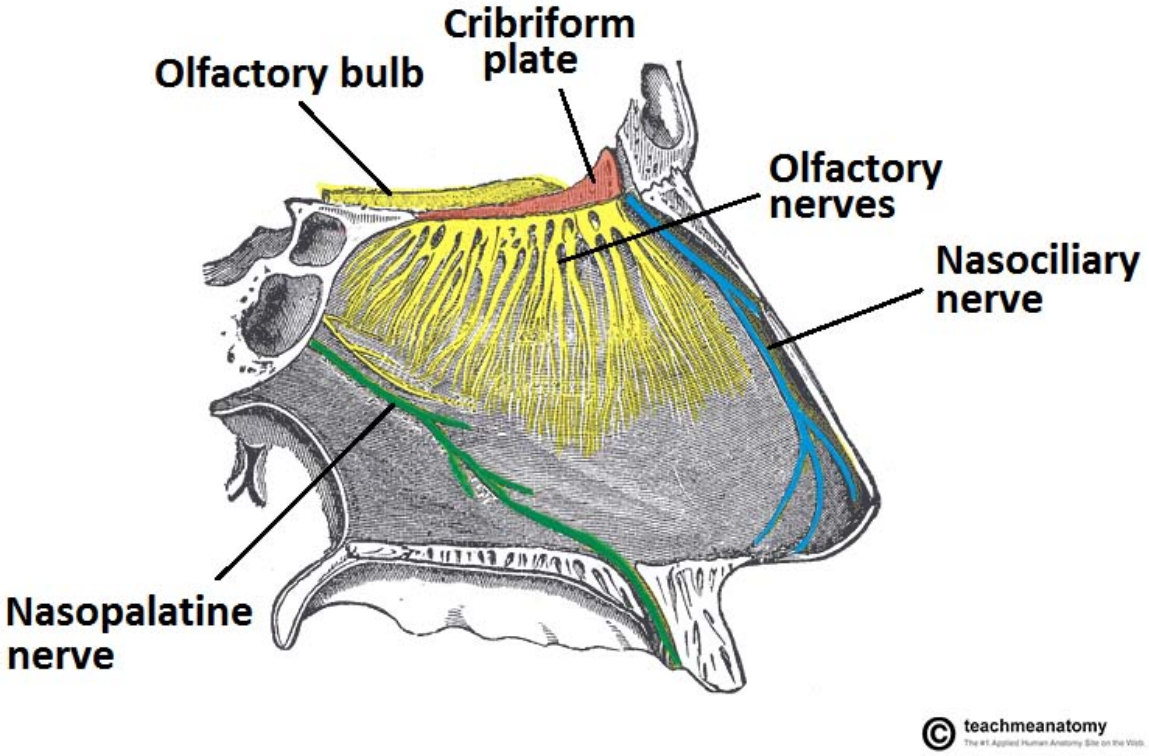

    - **Fracture of cribriform plate**
        - Exposes brain and meninges to external —> may result in infection
        - Irreversible damage of olfactory bulb —> anosmia thereafter

Paranasal sinuses

1. Frontal
2. Ethmoid (ant/mid/post)
3. Sphenoid
4. Maxillary

Functions: lighten head, humidify air, immune defence, increase voice resonance

Maxillary and ethmoidal sinuses are present at ***BIRTH*

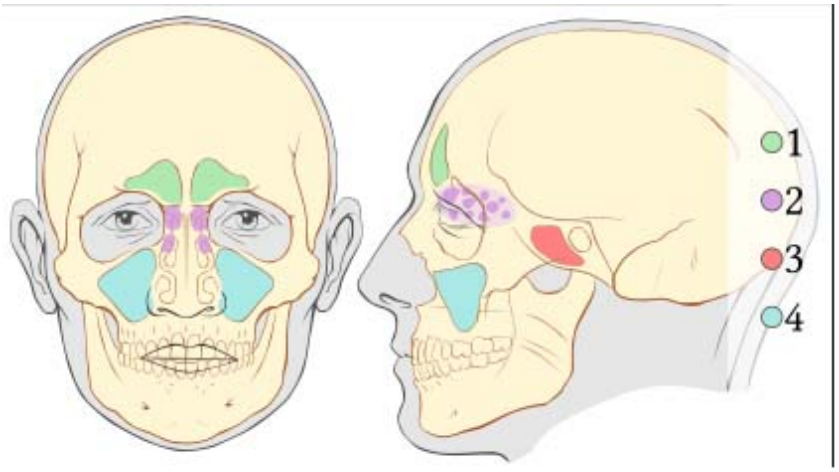

Facial glands

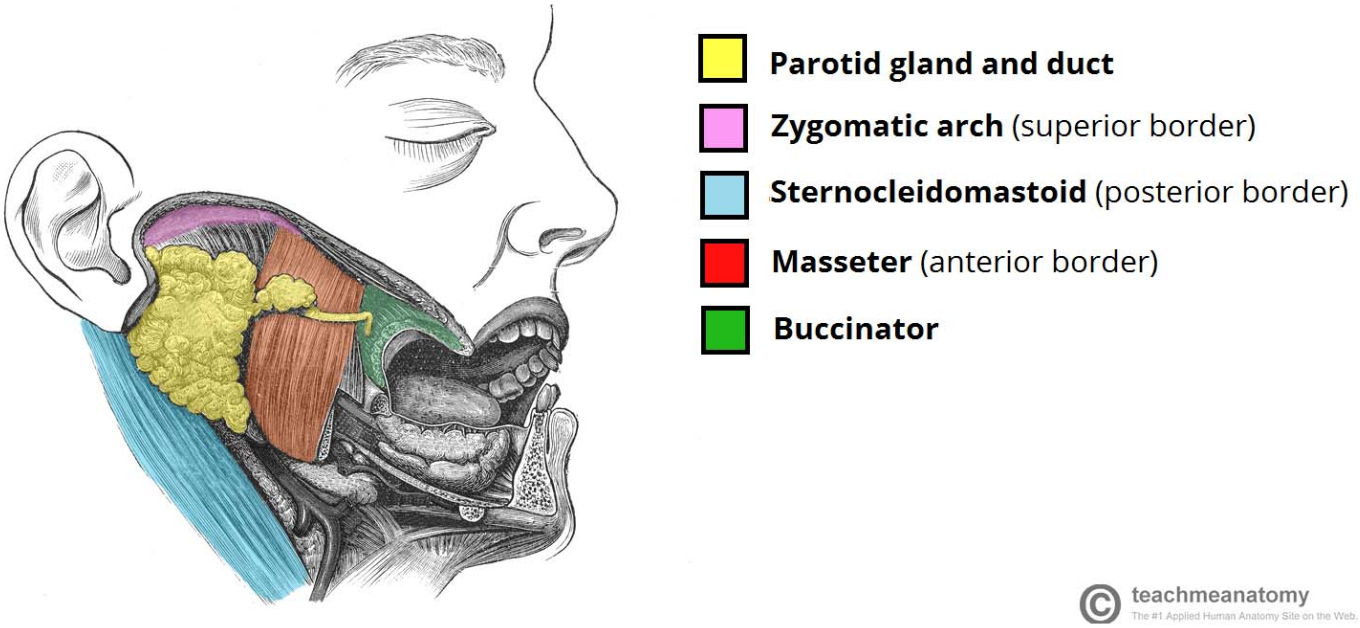

Parotid gland

- Duct travels over master and buccinator muscle —> near second upper molar empties into oral cavity
- Structures passing WITHIN gland
  1. Facial nerve gives rise to its 5 branches from within gland
  2. Ext carotid a
  3. Retromandibular vein (from sup temporal and maxillary veins converging)
- Innervation (complex)
  - Starts from glossopharyngeal —> synapse in Otic ganglion —> parasympathetic fibres travel in auriculotemporal nerve
    - Glossopharyngeal branches = Secretomotor function
    - Auriculotemporal = sensation
  - 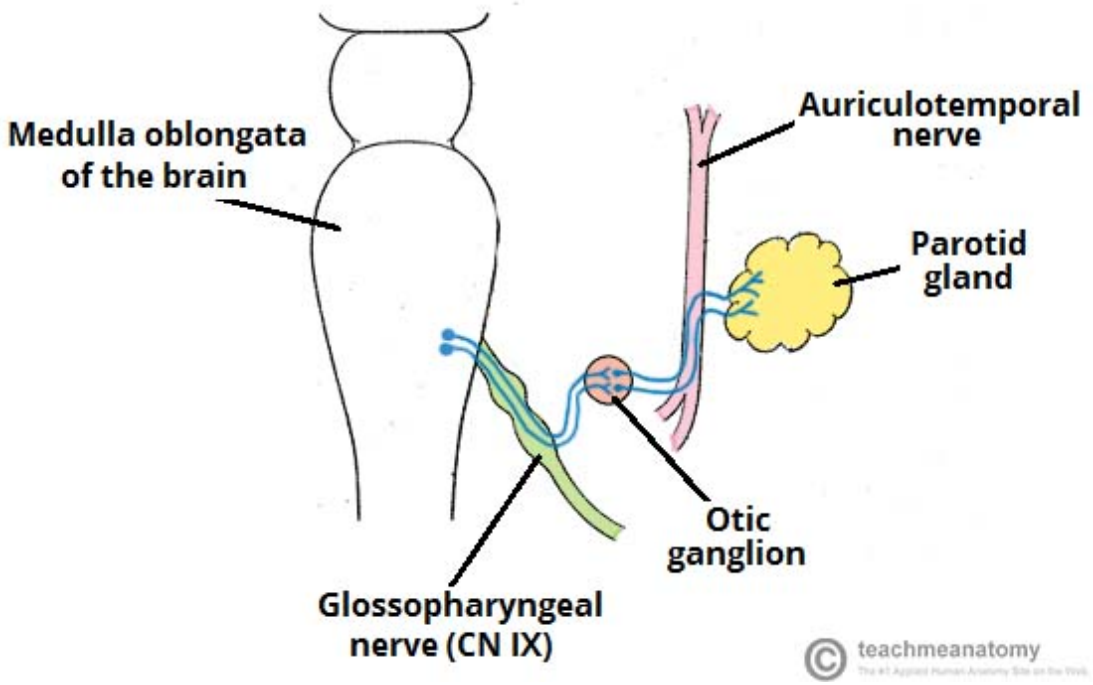

Tongue

Lymph drainage

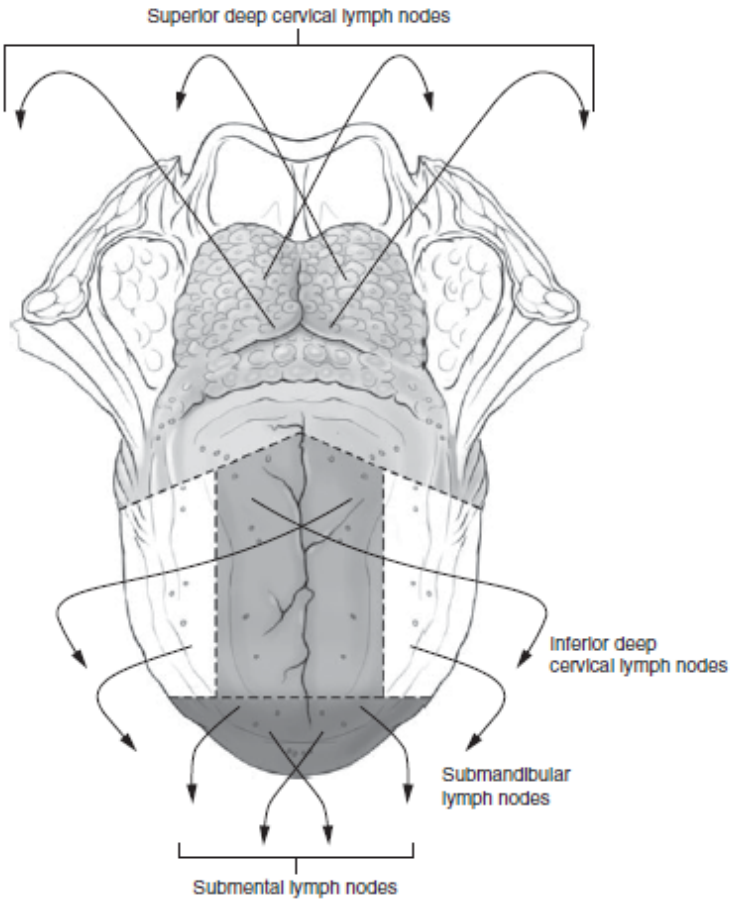

LYMPH DRAINAGE

- Deep cervical = divided into upper and lower
  - Most upper = JUGULODIGASTRIC - tonsils and tonsillar region
  - Most infe = JUGULO-OMOHYOID - tongue

- General topography: muscles, spaces & fascia
- Appreciation of the topography in terms of:
    - Postvertebral extensor musculature
    - Pre-vertebral flexor musculature
    - Presence and function of pre-vertebral fascia
    - The visceral of the neck as lying anterior to the pre-vertebral fascia
    - The thyroid as being enclosed in pretracheal fascia
    - trapezius & sternomastoid as lying within deep cervical fascia
- Specific requirements: Deep cervical fascia as comprising 4 components (eg carotid sheath)
- [Knowledge of the anatomy of each fascial component not required]
- Tissue spaces of the neck: [prevertebral, retropharyngeal, parapharyngeal, submandibular]
- Their locations
- The common pathways by which infection may spread from each
- Anatomical basis of Ludwig's angina

FASCIA OF THE NECK

Superficial fascia = immediately below skin and before deep fascia. Blends with platysma

Deep fascia (4 layers - superficial to deep:)

1. Investing fascia (superficial layer of deep)
    - Envelopes SCM and trapezius muscles
2. Pre-tracheal fascia
    1. Envelopes muscles anteriorly and trachea and oseophagus posteriorly
3. Pre-vertebral fascia
    1. Surrounds vertebral column and its associated muscles
4. Carotid sheath
    1. Common carotid a
    2. Internal jugular v
    3. Vagus n

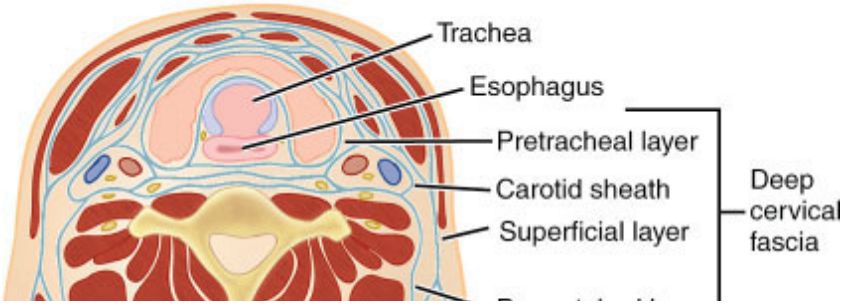

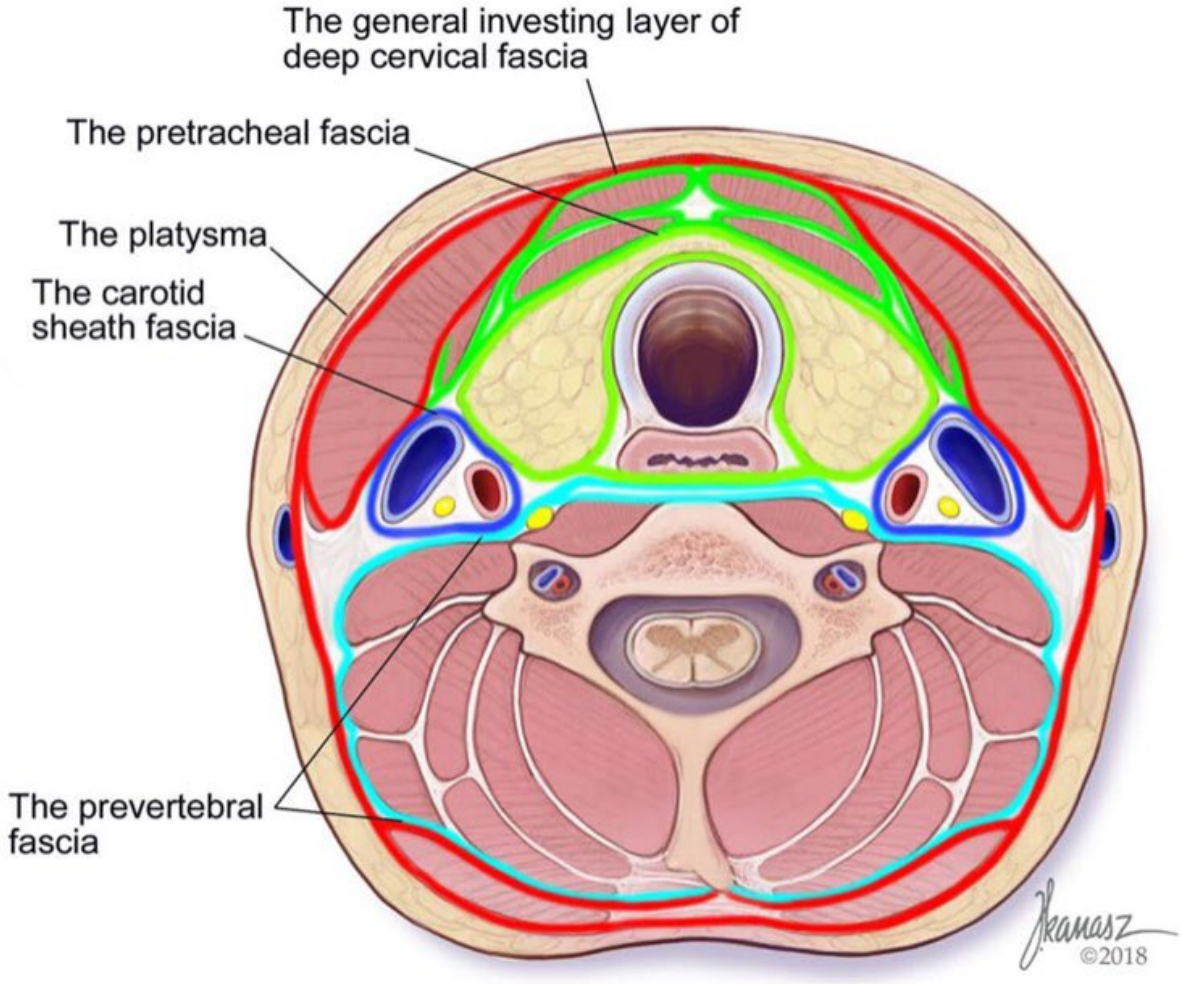

SPACES:

1. Prevertebral space =
   - within the prevertebral layer
2. Retropharyngeal =
   - between pretracheal and prevertebral layers
   - 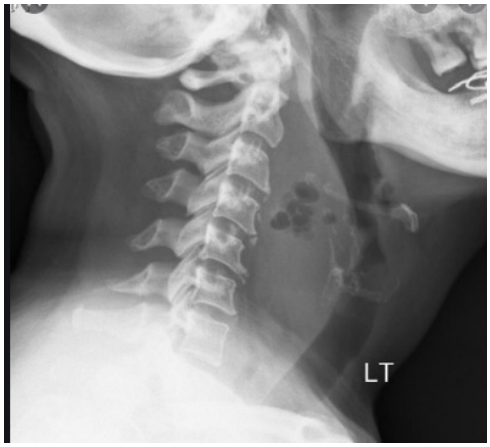

     - = Massive retropharyngeal abscess pushing trachea anteriorly

Massive retropharyngeal abscess pushing trachea anteriorly.

- Emergency presentation, normally needs intubation

3. Parapharyngeal space
   - Lateral to nasal pharynx
   - 

     = shows paraphayngeal abscess in this space
4. Submandibular space
   - Between mylohyoid and deep investing fascia
   - LUDWIGS Angina involves this AND sublingual space - floor of mouth pushed down, tongue pushed up
   - Dental abscesses can spread to this space
   - 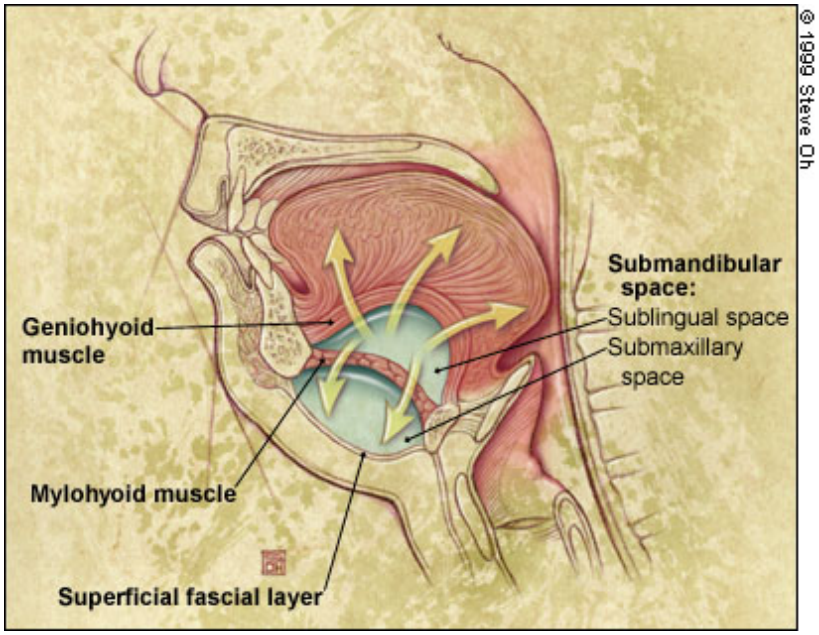

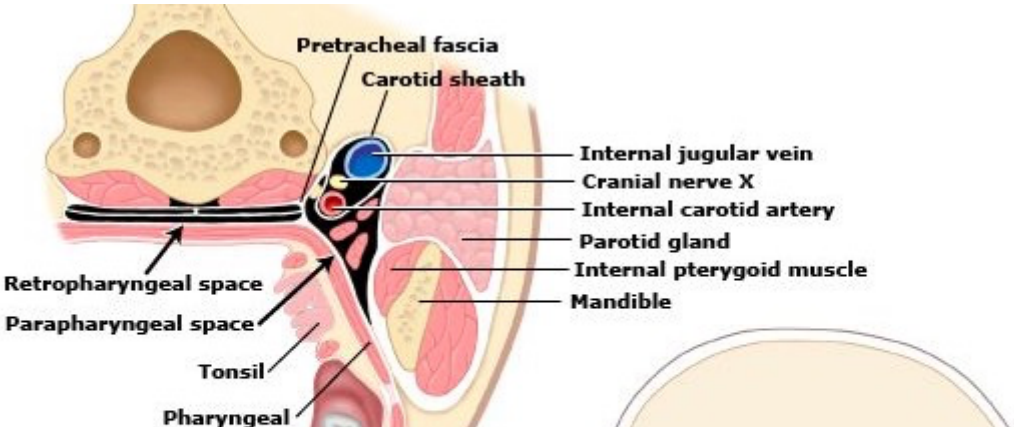

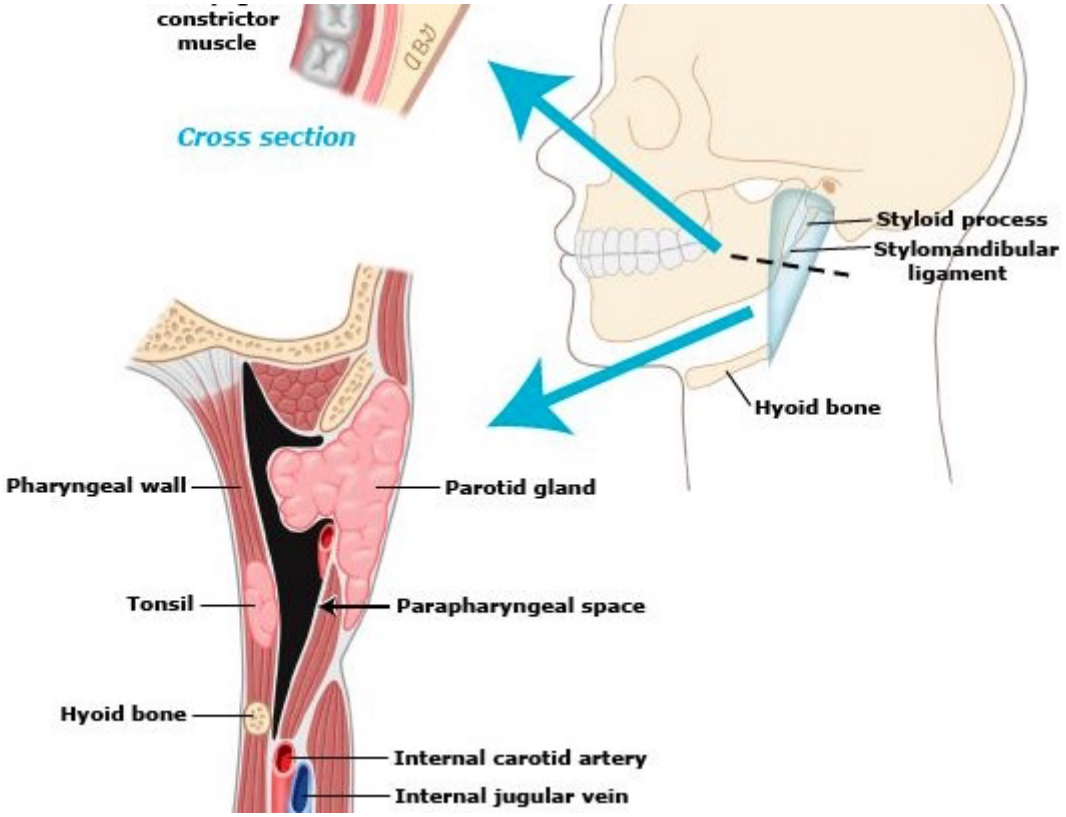

SCM

- Extends neck/head and lateral rotation to opposite side
- Accessory n (CN XI, i.e. C2-3)

Suprahyoid muscles

- 4 muscles
- Elevate hyoid as part of swallowing (early part of action)

Infrahyoid muscles

- 4 muscles
- Depress the larynx, part of swallowing (later part of action)

Thyroid

- Isthmus below cricothyroid membrane - is attached to 2nd and 3rd tracheal rings

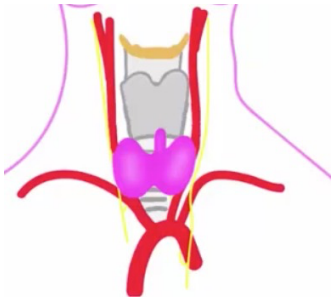

- **Cricothyroidotomy** = at cricothyroid membrane (between thyroid cartilage (superiorly) and cricoid cartilage (inferiorly))
- **Tracheostomy** = between 2nd and 3rd or 3rd and 4th tracheal rings

---

Cervical sympathetic trunk

- From the sympathetic trunk (thoracolumbar T2-L2 sympathetic chain)
- Cervical trunk = superior, middle and inferior cervical ganglia
  - 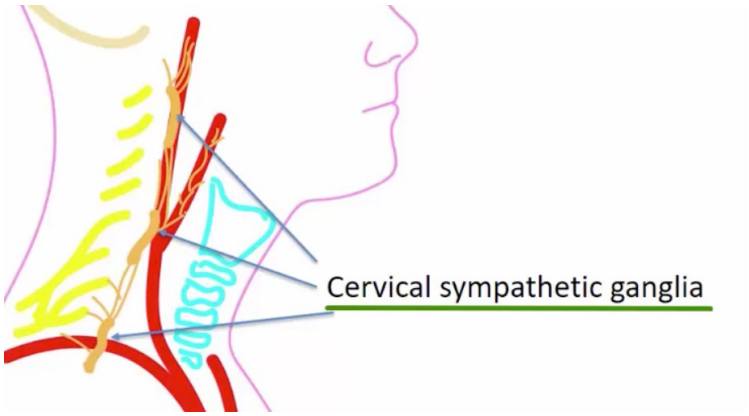

  - Plexus of nerves wrap around and follow carotid arteries
  - <u>BRANHCES</u>
    - Somatic branches —> to C1 to C8
    - Visceral branches to cardiac plexuses
    - Vascular branches to dilator pupillae (horners syndrome = miosis (constriction of pupil))

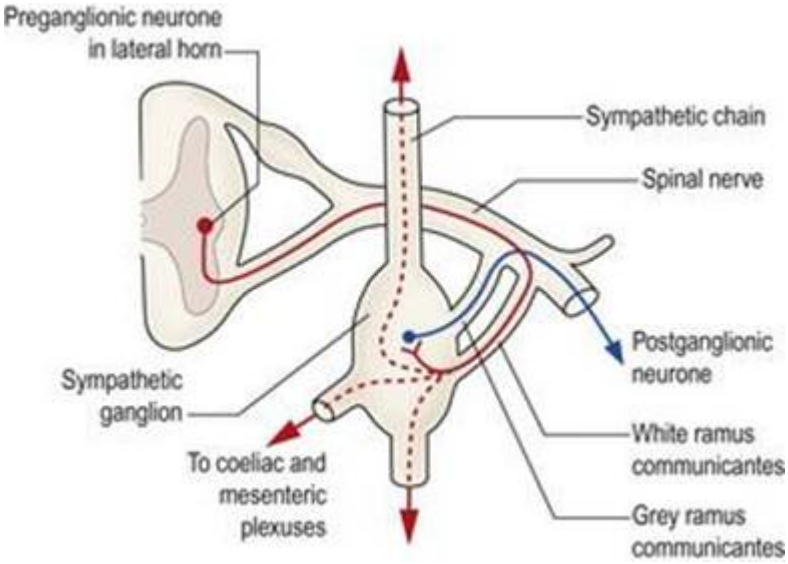

Sympathetic chain ganglia synapse with Cervical spinal nerves via the grey rami communicates

Horners syndrome

- Lesion to any part of sympathetic nervous system:

1. Spinal cord level e.g. syringomyelia
2. Root level e.g. brachial plexus injury to T1
3. Ganglion e.g. penetrating trauma
4. Lung apex e.g. pan coast tumour
5. Carotid artery where the chain follows along e.g. carotid aneuyrsm

---

ROOT OF THE NECK

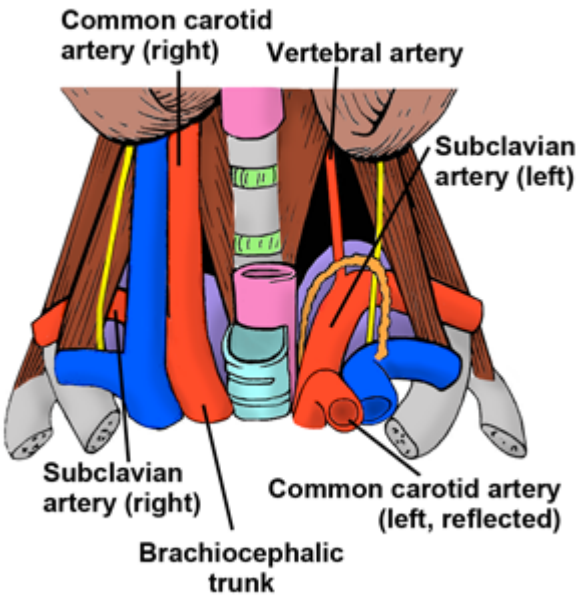

Scalenes anterior

- C3-6 vertebral bodies to first rib
- Separates subclavian artery from vein
- Phrenic nerve runs down front of scalene anterior

Thoracic duct - on LEFT side (orange duct on picture) - hence right side preferred for subclavian cannulation
Recurrent laryngeal nerve around subclavian artery

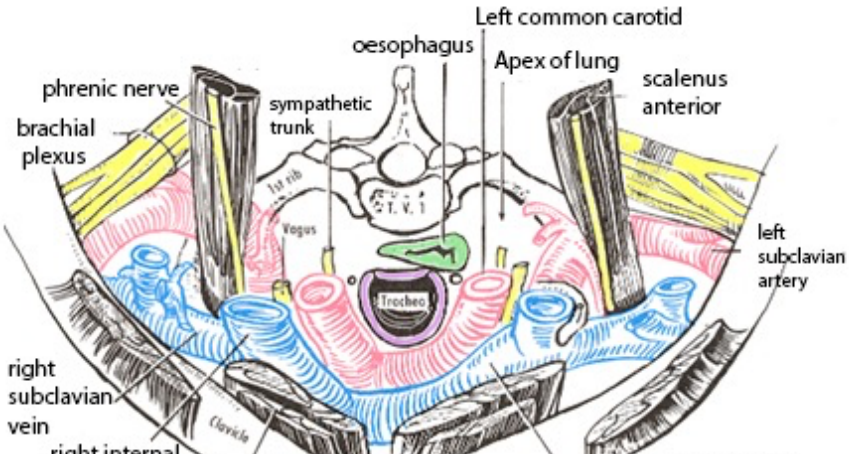

Nervous

- Phrenic nerve
- Sympathetic trunk
- Recurrent laryngeal
- Vagus nerves

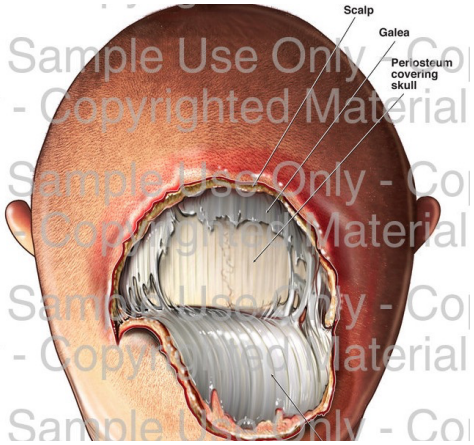

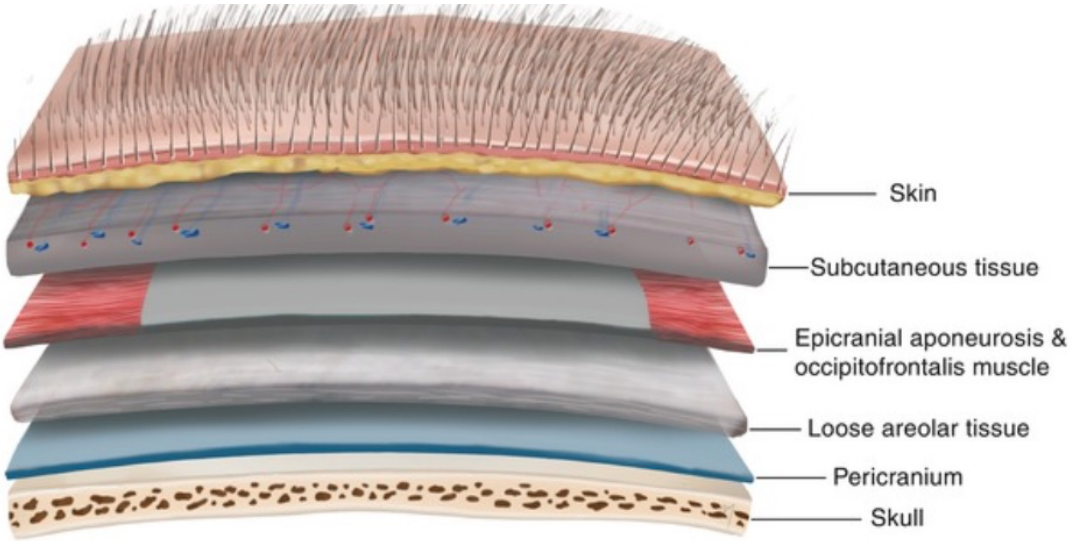

LAYERS

- **S**kin
- **C**utaneous tissue
- **A**poneurosis (galea - connecting occipitals and frontalis muscles)
- **L**oose connective/areolar tissue - DANGER ZONE AS INFECTION CAN SPREAD HERE IF BREACHED - e.g.

if galea is open

- **P**ericranium
- **S**kull

Scalp injuries - always check if the galea (loose connective tissue layer) is injured.

<u>Galea (fronto-occipital aponeurosis)</u>

Superficial scalp wounds do not gape because of the strength of the underlying aponeurosis, which holds the margins of the wound together. However, if the aponeurosis is lacerated in the coronal plane, deep scalp wounds gape because of the contraction of the frontalis and occipitalis muscles, which contract in opposite directions

- This **must** be separately closed, otherwise two potential complications:
  1. Tracking of infection into veinous system and CSF —> meningitis
  2. It anchors the frontalis muscles - can lead to significant asymmetry of facial expression
    1. 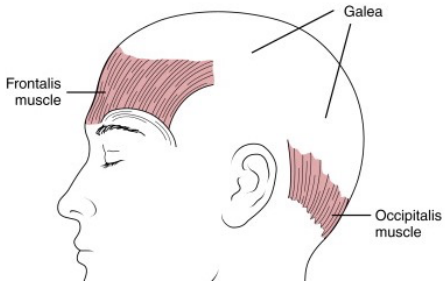

    2. Occipitalis muscle = attached to occipital bone
    3. Frontalis muscle = attached to skin and CT front of face, so contraction = lifts eyebrows

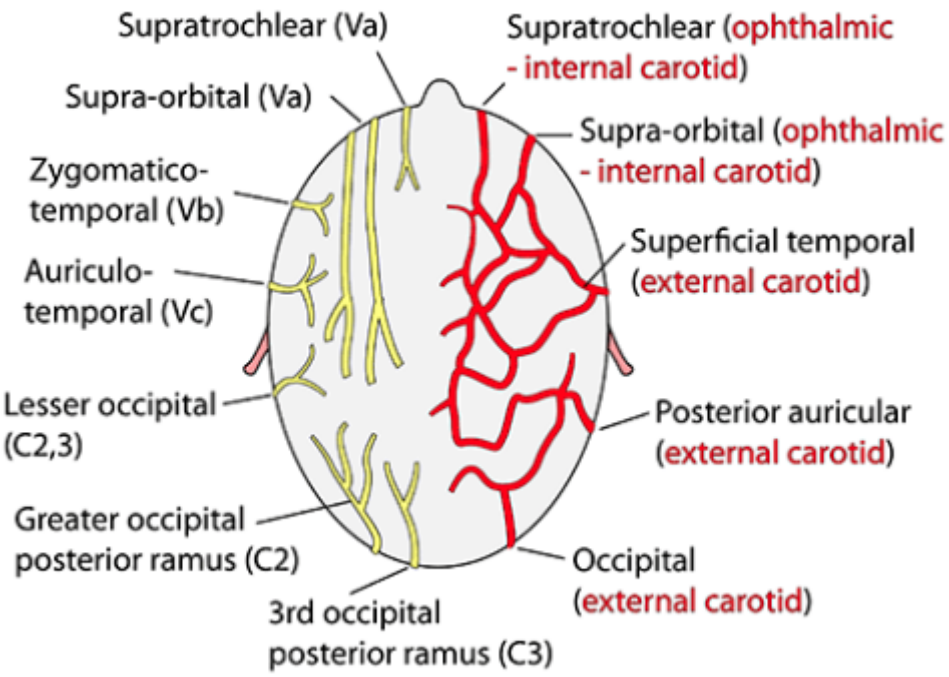

ORAL CAVITY

ORAL CAVITY

Hard palate

- Two bones
  - Front = palatine process of maxilla
  - Back = horizontal plate of palatine bone
- 3 foramen
  - 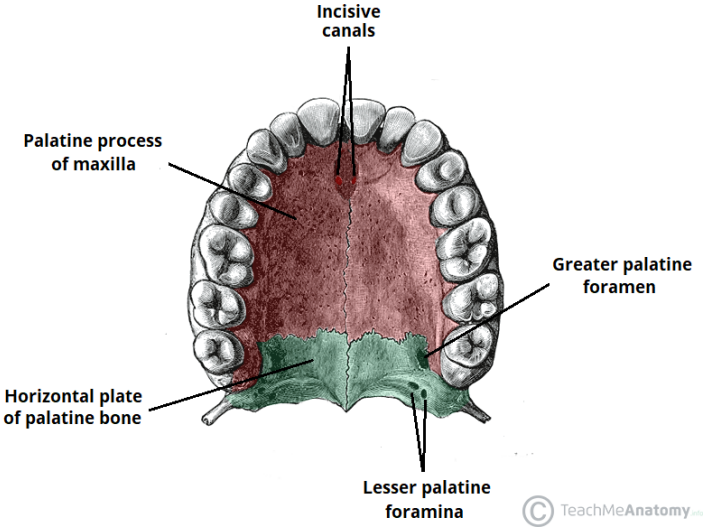

  - Incisive canals/foramen = behind incisors, nasopalatine nerve + vessels
  - Greater palatine foramen - medial to 3rd molars, greater palatine nerve
  - Lesser palatine foramen - at palatine pyramid - lesser palatine nerve
- Innervation
  - Upper cavity = **Maxillary (V2)**
    - Roof
      - —>Hard palate = nasopalatine n
      - —>soft palate = lesser palatine n
    - —>glandular structures = greater palatine n
    - —>mucosa = buccal branch (V3)
  - Lower cavity = **Mandibular (V3)**
    - Tensor vali palitini, mylohyoid
- Vasculature
  - Roof = greater palatine arteries
  - Venous drainage = pterygoid venous plexus

Gag refles

- Afferent = glossopharyngeal nerve
- Efferent = vagus nerve

Tonsils

- Adenoids
  - —> drain to deep cervical and retropharyngeal nodes
- Palatine
  - —> drain to jugolodigastric and deep cervical lymph nodes
- Lingual
  - —> drain to deep cervical nodes

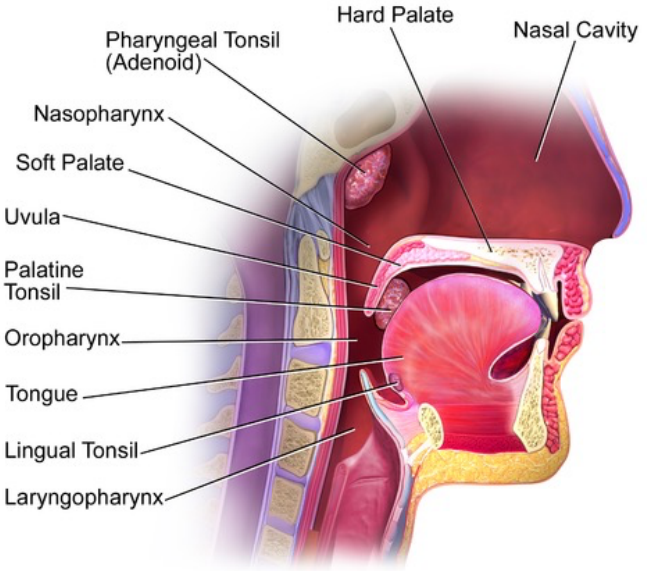

All of the muscles of the pharynx receive motor supply from the vagus nerve (CN X) except for stylopharyngeus muscle which receives motor supply from the glossopharyngeal nerve (CN IX)

All the tonsil groups (lingual, adenoid and palatine) ultimately drain to the deep cervical lymph nodes

LYMPH DRAINAGE

- Deep cervical = divided into upper and lower
  - Most upper = JUGULODIGASTRIC - tonsils and tonsillar region
  - Most infe = JUGULO-OMOHYOID - tongue

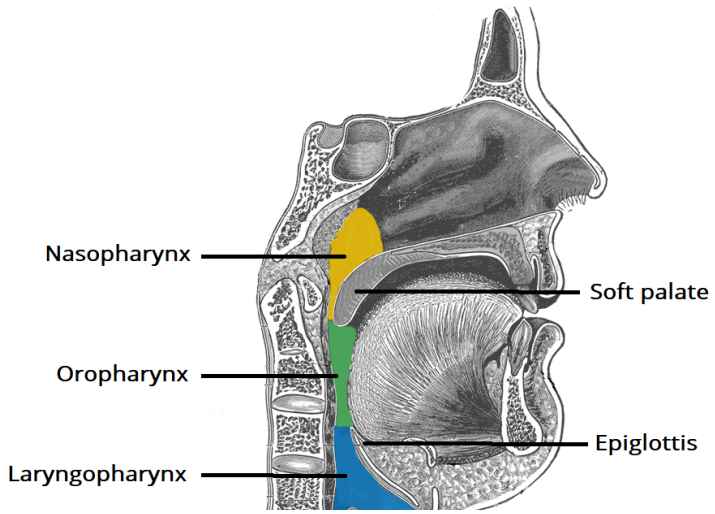

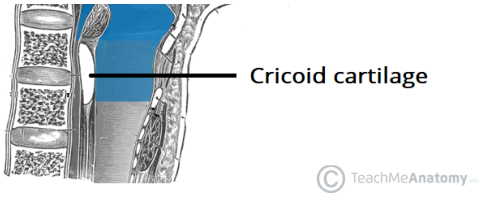

- Nasopharynx = trigeminal
- Oropharynx = glossopharyngeal
- Laryngopharynx = vagus

Pharynx

- Base of skull to C6
- Naso—>oro—>laryngo
- Posterior relation = pre vertebral fascia
- Lymph drainage
  - Deep cervical nodes
- Motor supply
  - All muscles (except stylopharyngeus) innervated by VAGUS
  - Stylopharyngeus innervated by GLOSSOPHARYNGEAL
- Sensory
  - Nasopharynx = maxillary n (V2)
  - Oropharynx = glossopharyngeal (think gag reflex)
  - Laryngopharnx = vagus n
- Eustachian tube opens into nasopharynx

Larynx

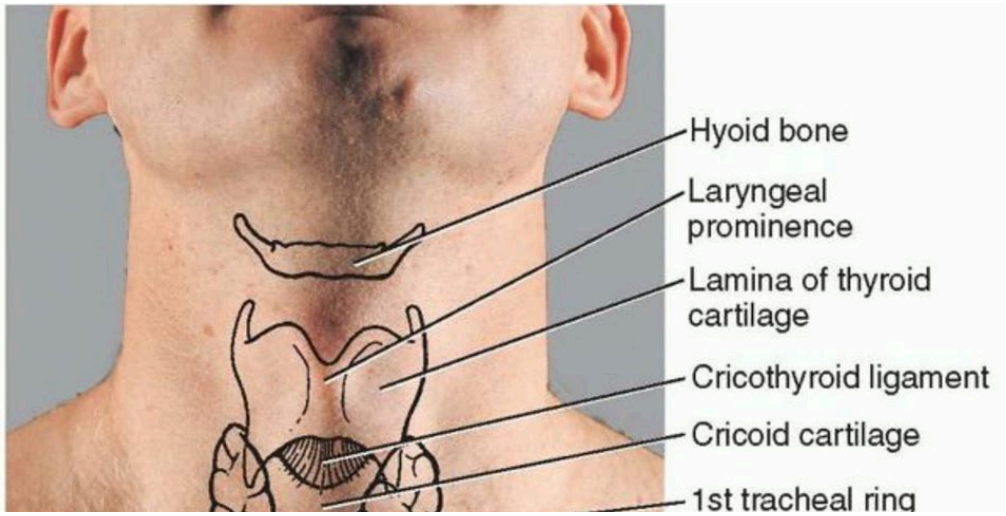


Isthmus
Lobes
of thyroid gland

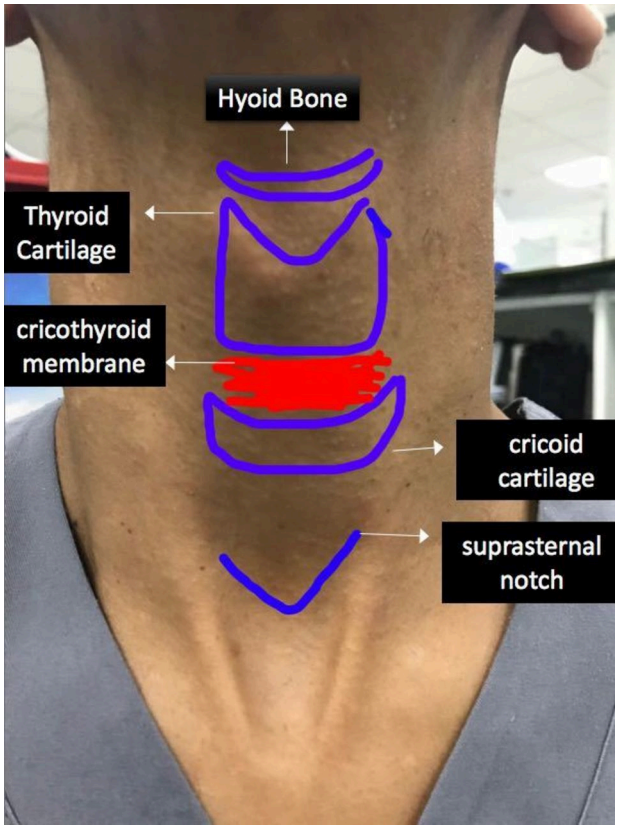
Hyoid Bone
Thyroid Cartilage
cricothyroid membrane
cricoid cartilage
suprasternal notch

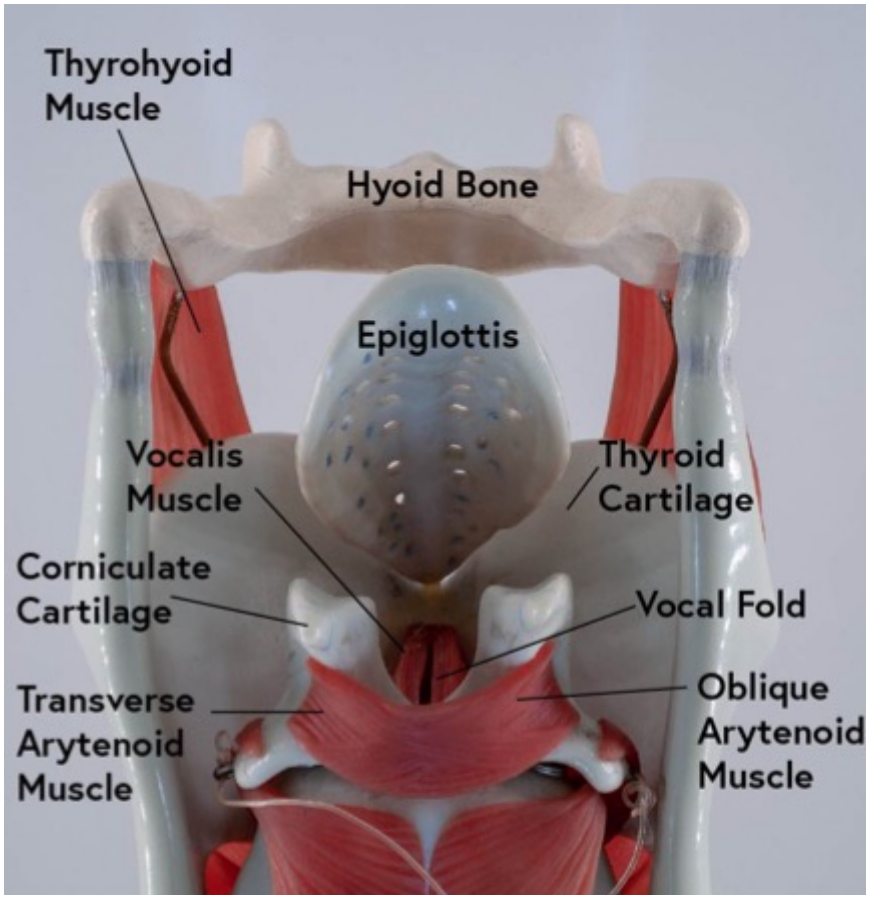
Thyrohyoid Muscle
Hyoid Bone
Epiglottis
Vocalis Muscle
Thyroid Cartilage
Corniculate Cartilage
Vocal Fold
Transverse Arytenoid Muscle
Oblique Arytenoid Muscle

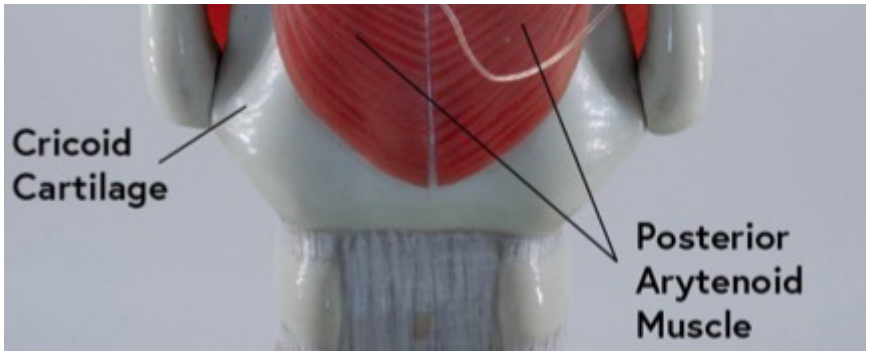

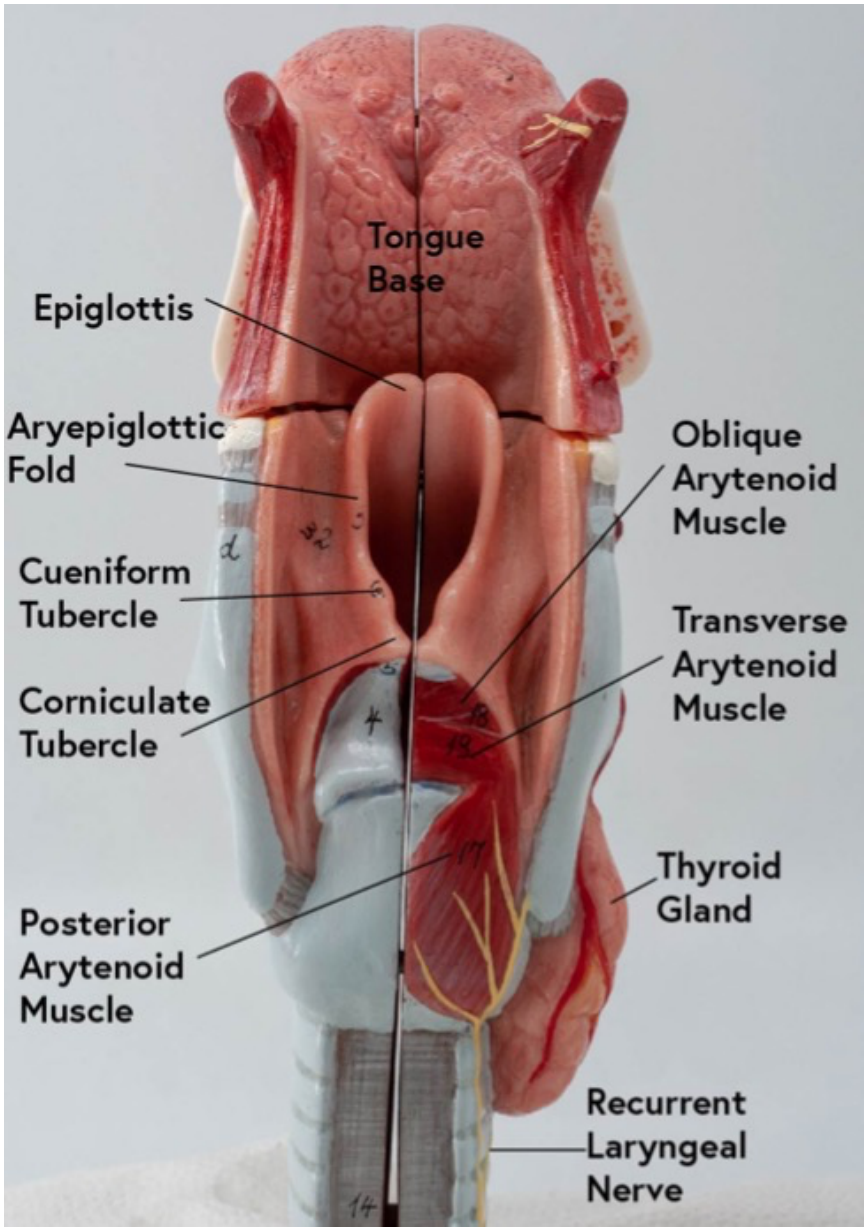

EMERGENCY CRICOTHYROIDOTOMY:

- Cut through cricothyroid membrane/ligament

Suspended from hyoid bone
C3-C6

- Supraglottis
- Glottis
- Infraglottis

Cricothyroidotomy vs tracheostomy

- Cricothyroidotomy:
  - Typically emergency or urgent setting
  - Placed between cricoid and thyroid cartilages
  - Often converted to tracheotomy if longer term need
- Tracheostomy:
  - Often planned, in surgical/asceptic setting
  - Placed between 2nd and 3rd tracheal rings

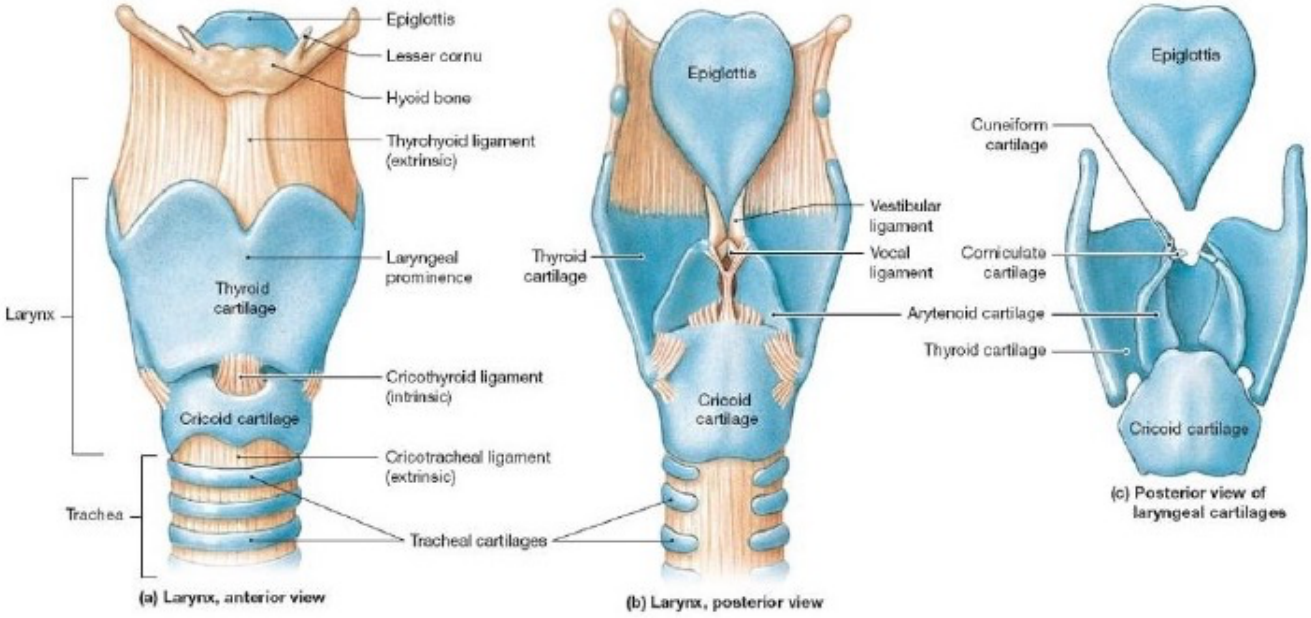

Cartilages

- Three unpaired
  - Epiglottis
  - Thryoid
  - Cricoid - the only complete circle of cartilage
- Three paired
  - Cuneiform
  - Corniculate
  - Arytenoids

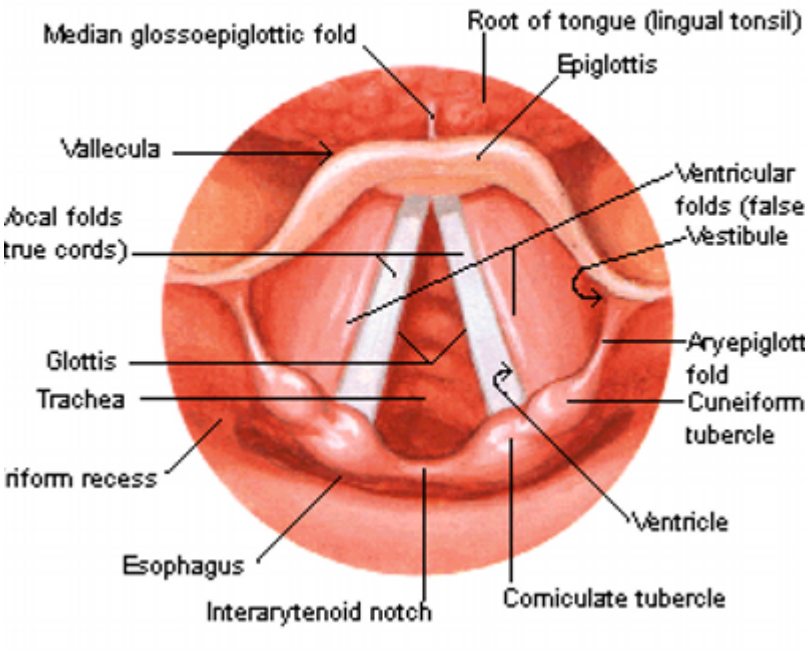
Median glossoepiglottic fold
Root of tongue (lingual tonsil)
Epiglottis
Vallecula
Ventricular folds (false
Vestibule
Vocal folds
true cords)
Aryepiglott
fold
Glottis
Trachea
Cuneiform
tubercle
riform recess
Ventricle
Esophagus
Interarytenoid notch
Corniculate tubercle

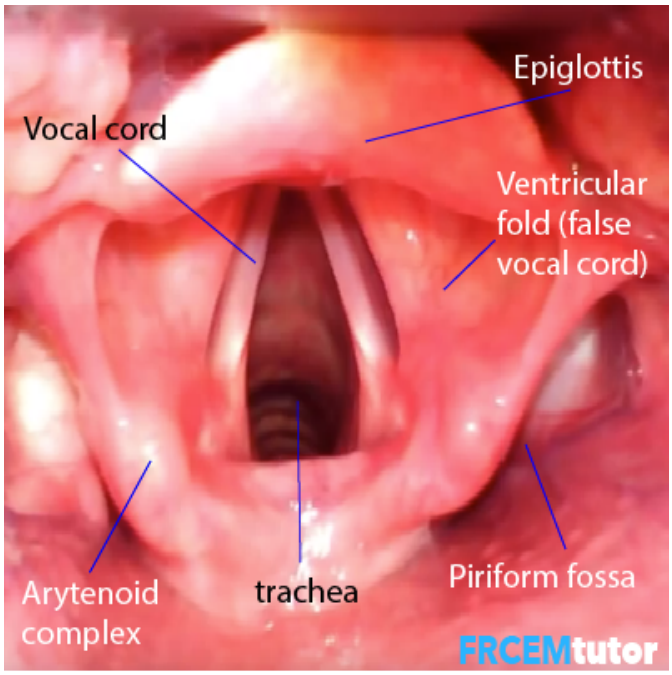
Epiglottis
Vocal cord
Ventricular
fold (false
vocal cord)
Arytenoid
complex
trachea
Piriform fossa
FRCEMtutor

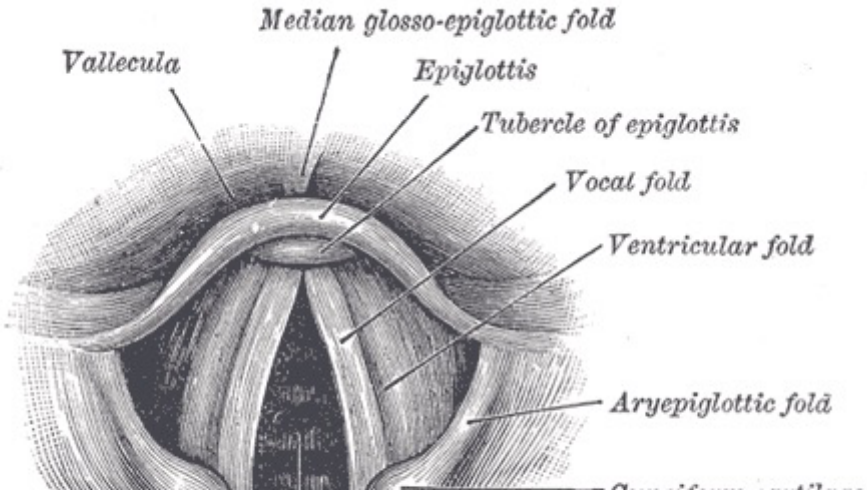
Median glosso-epiglottic fold
Vallecula
Epiglottis
Tubercle of epiglottis
Vocal fold
Ventricular fold
Aryepiglottic fold



JOINTS

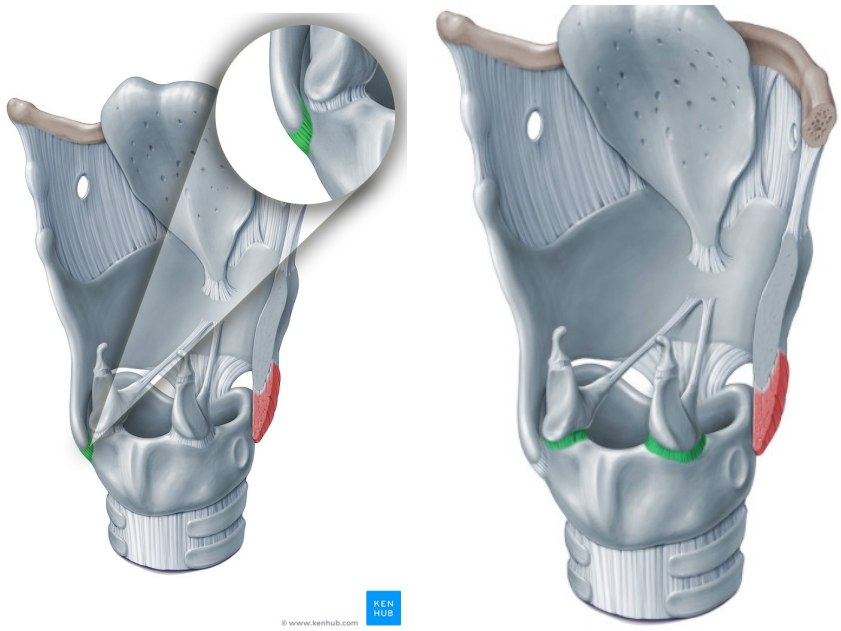

LEFT - cricothyroid joint
RIGHT - cricoarytenoid joint

Muscles = extrinsic and intrinsic

- Extrinsic - supra and infra hyoid groups of muscles. Support and position larynx within trachea via elevation/depression
- Intrinsic - alter size and shape of inlet and move vocal folds
    - *Recurrent laryngeal nerve innervation of intrinsic muscles*

innervation

- Recurrent laryngeal n - sensation infra glottis + intrinsic muscles
- Superior laryngeal - sensation supra glottis and cricothyroid muscle

Gag reflex -

- afferent - glossopharyngeal
- efferent - vagus