Upper limb

Pectoral

- Pec major
  - Lat and medial pec nerve (C5 to T1)
- Pec minor
  - Medial pec nerve nerve (C8 and T1)
- Trap
  - Accessory nerve (CN XI)
  - Scapular retraction, elevation and depression
- Lat dorsi
  - Thoracodorsal nerve (C6 to C8)
- Serratus anterior
  - Long thoracic nerve (C5 to C7 - runs posterior to mid-axillary line, so chest drains are in anterior axillary line)
  - Scapular protraction, depression
  - 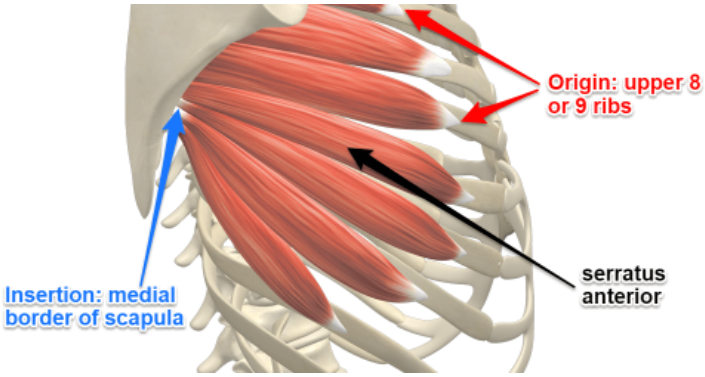

  - 

    Winging scapula if damaged LT nerve (can't protract scapula)

SCJ

- Is the only attachment of upper limb to axial skeleton
- 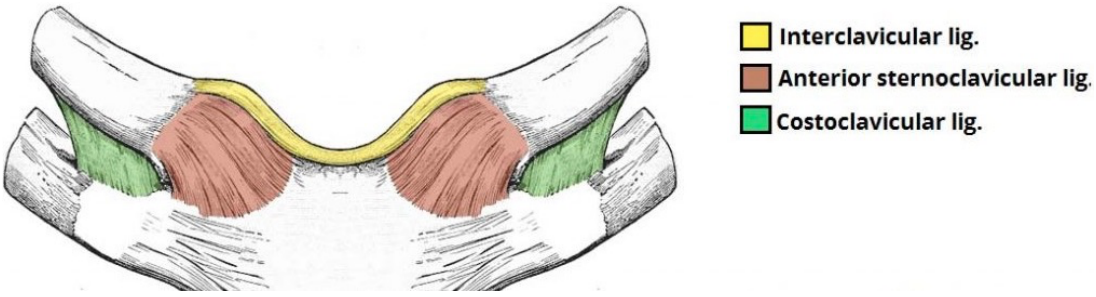

ACJ

- *Function is to allow pectoral movement*
- 3 ligaments that strengthen the ACJ
  - 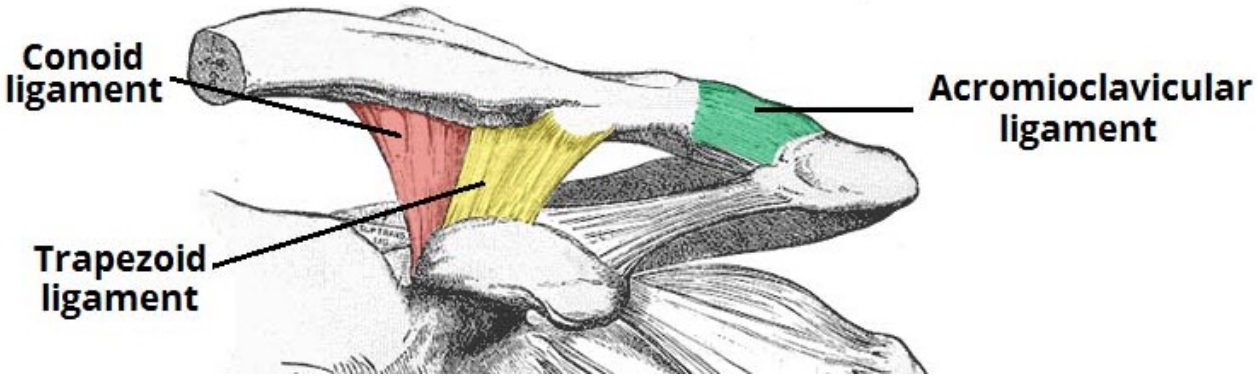

    - Acromioclavicular lig
    - Coracoclavicular ligs
      - Conoid
      - Trapezoid
- Some axial rotation and anteroposterior movement allowed
- Disclocation
  - 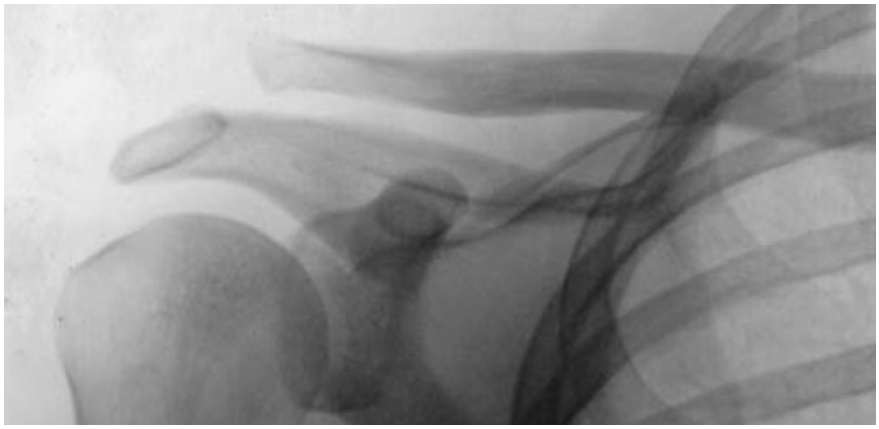
  - Direct blow to joint or fall onto outstretched hand
  - Worse if rupture of any of the 3 ligaments occurs = upper limb not supported, shoulder moves inferiorly

Shoulder joint

- Bursae
  - 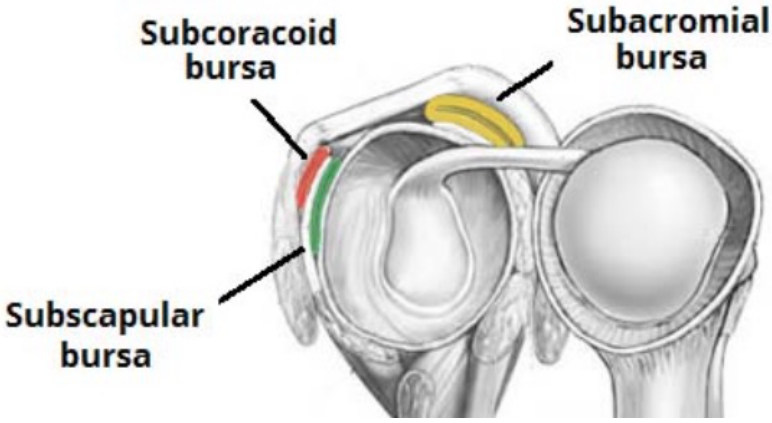

  - Reduce wear and tear
- <u>Ligaments</u>
  - Glenohumeral (superior/middle/inferior) - forms the actual joint capsule

- Coracohumeral ligament
- **Coracoacromial ligament**
  - *Constitutes the coracoacromial arch* - stops the humeral head displacing superiorly
  - 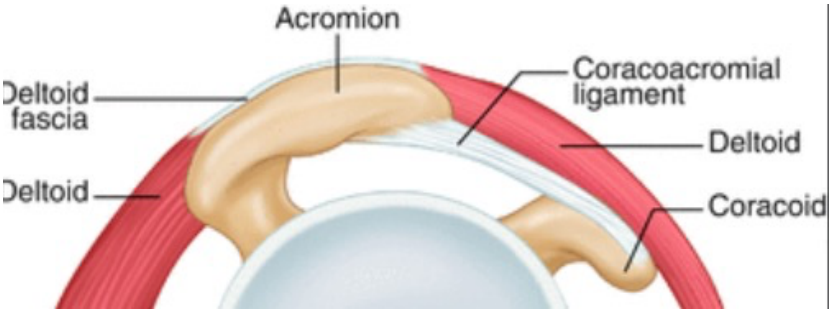

- Transverse humeral lig - holds tendon of long head bicep in intertubercular groove
- 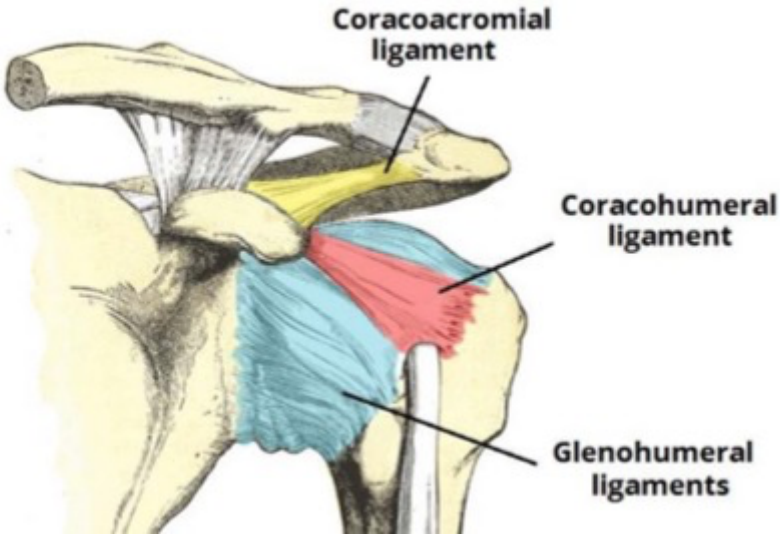

Rotator cuff

Hold humerus in place in glenoid fossa

- Subscapularis
  - Int rotation
  - subscapular nerve (C5-6)
  - *Hand off lower back test*
- Supraspinatus
  - Abduction (first 15 degrees —> deltoid up till 90 degrees —> trapezius beyond this)
  - Suprascapular nerve (C5)
  - *Empty can test at 30 degrees abduction*
- Infraspinatus
  - Ext rotation
  - Suprascapular nerve (C5-6)
  - *Resist int rotation*
- Teres minor
  - Ext rotation
  - Axillary nerve (C5)
  - *Resist int rotation*

Supraspinatus, infraspinatus, teres minor —> insert onto GREATER tubercle humerus

Subscapularis —> inserts onto LESSER tubercle humerus

Teres major vs minor

- Major - inserts interntubercular sulcus (anterior) = *INTERNAL rotation*
  - *Lower subscapular nerve*
- Minor - inserts greater tubercle = *LATERAL rotation*
  - *Axillary nerve*

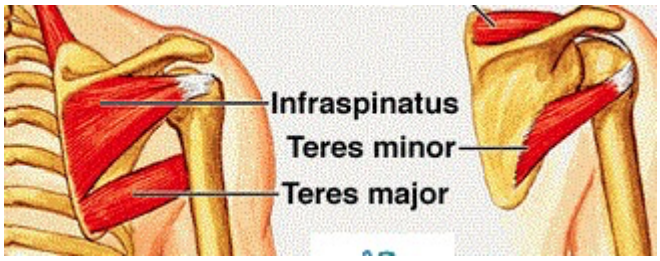

Muscle	Innervation	Nerve Root Origin
Supraspinatus	Suprascapular Nerve	C5
Infraspinatus	Suprascapular Nerve	C5 C6
Teres Minor	Axillary Nerve	C5
Subscapularis	Upper and lower subscapular nerve	C5 C6

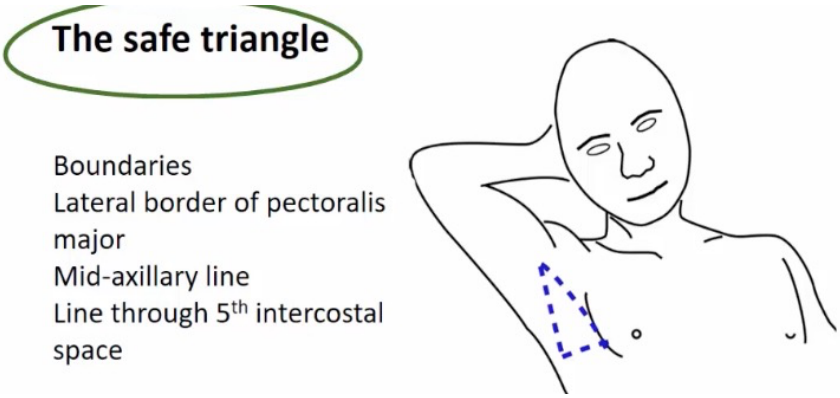

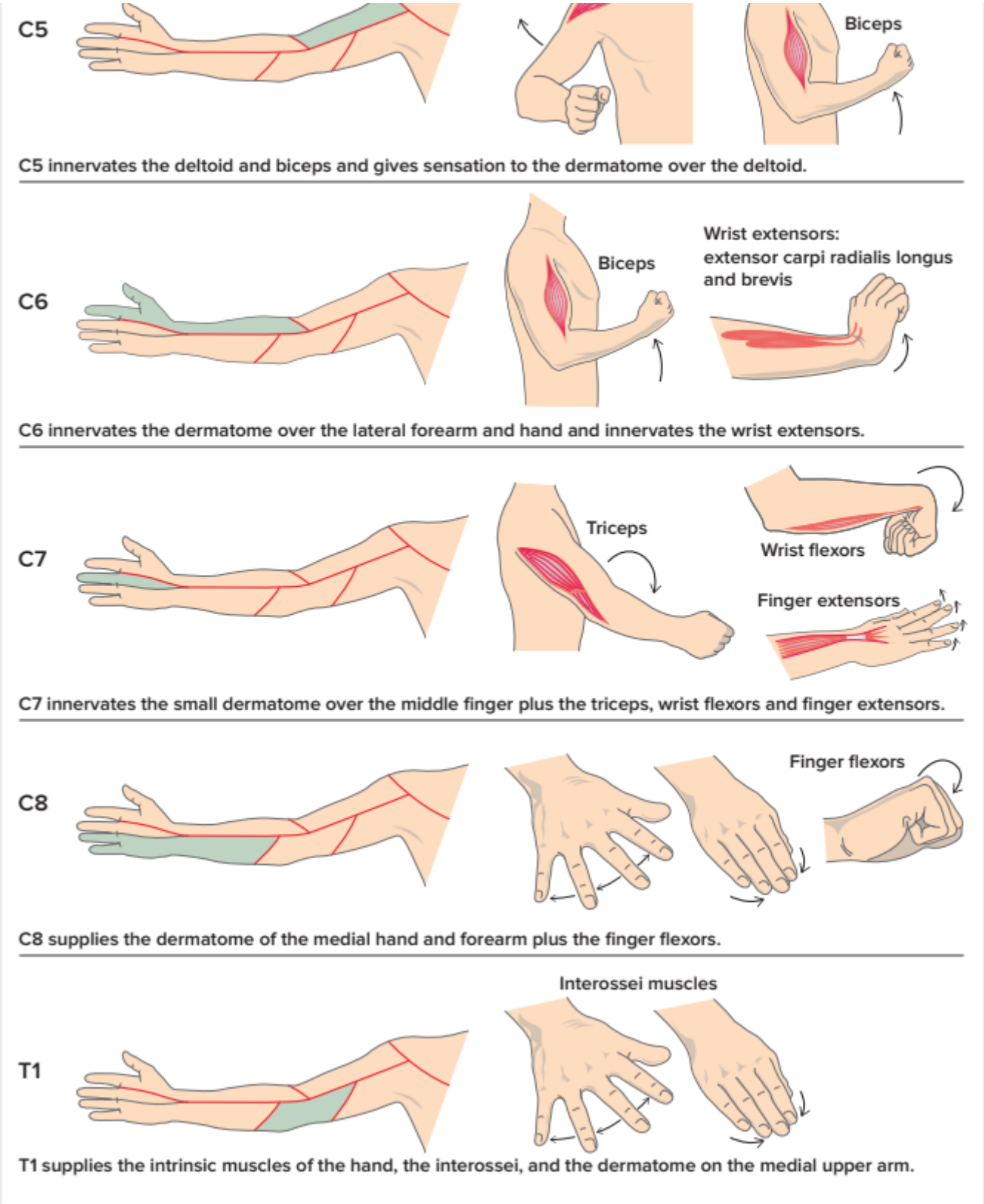

Brachial plexus

Remember, nerves are vertebral body +1. So C8 nerve is below C7 (no C7 vertebra)

- Root-trunk-division-cord
- Ventral rami C5 - T1
- 

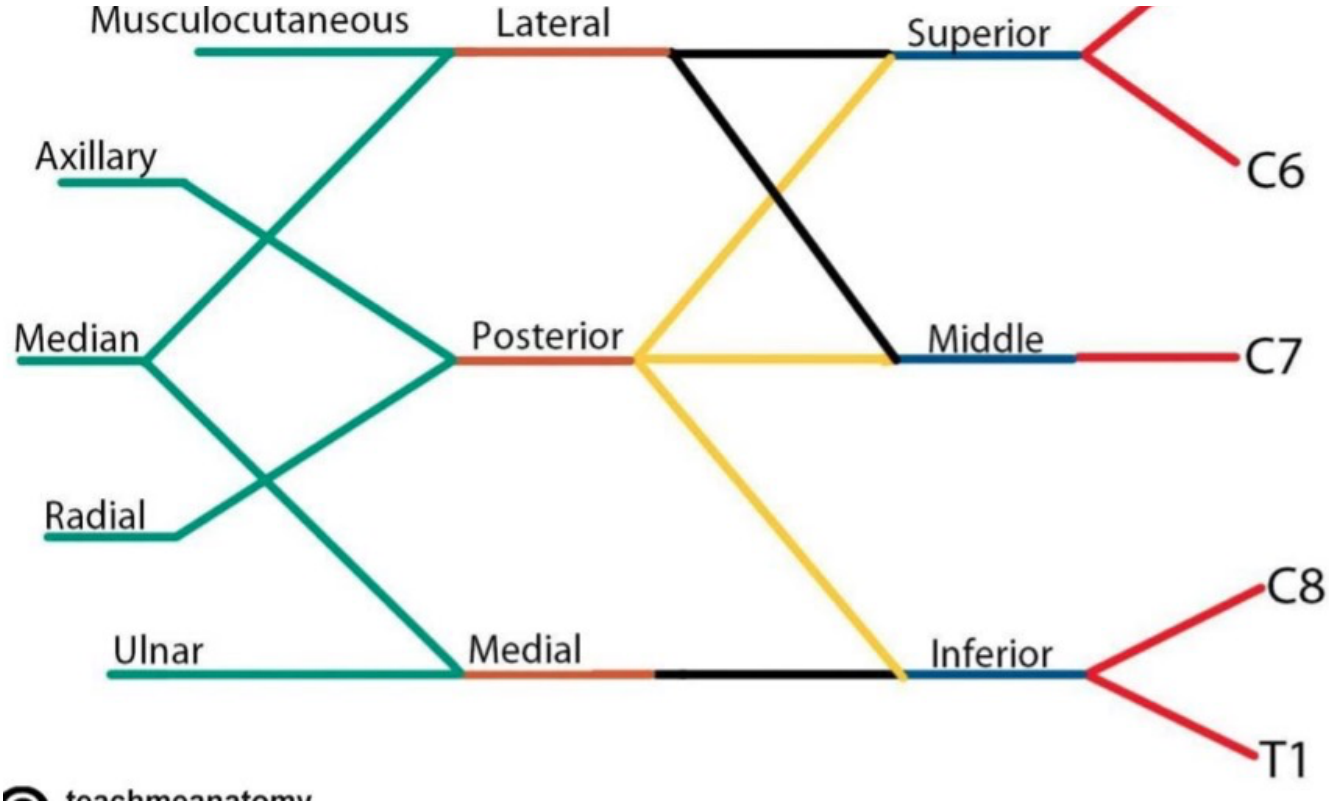
Musculocutaneous
Lateral
Superior
Axillary
C6
Median
Posterior
Middle
C7
Radial
C8
Ulnar
Medial
Inferior
T1

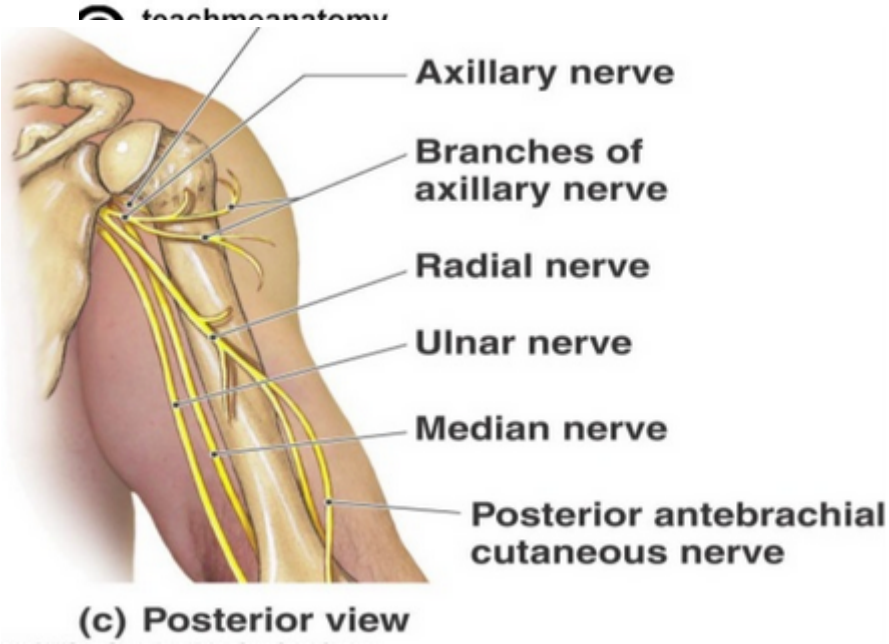
Axillary nerve
Branches of axillary nerve
Radial nerve
Ulnar nerve
Median nerve
Posterior antebrachial cutaneous nerve
(c) Posterior view

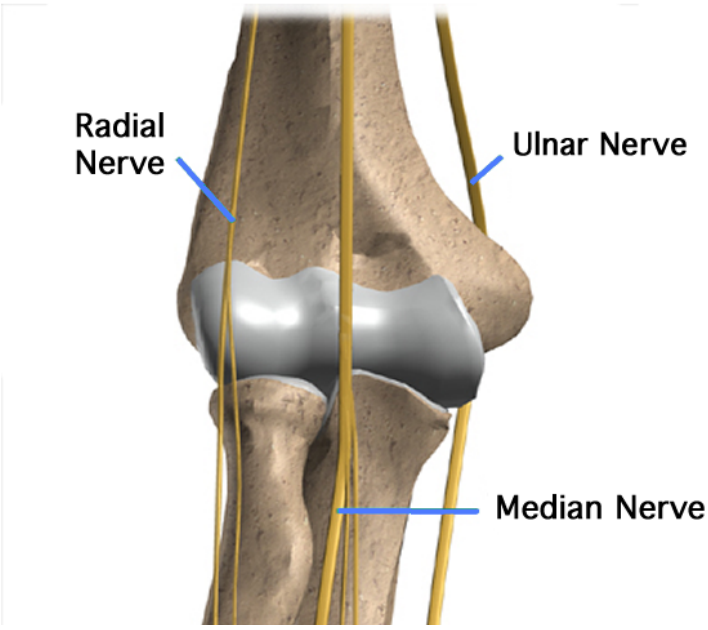
Radial Nerve
Ulnar Nerve
Median Nerve

- **Musculocutaneous**
  - From lateral cord
  - 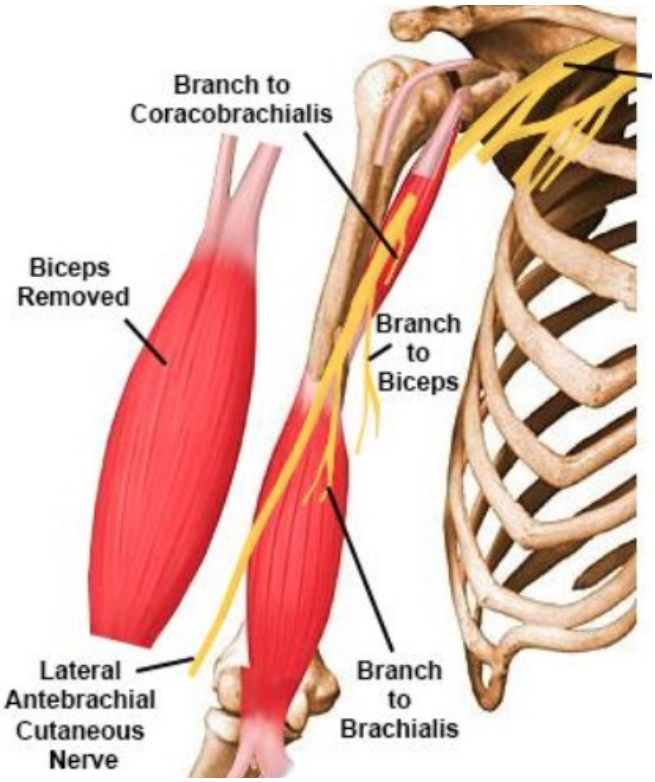

  - Motor:
    - Biceps
    - Coracobrachialis
    - Brachialis
- **Axillary**
- 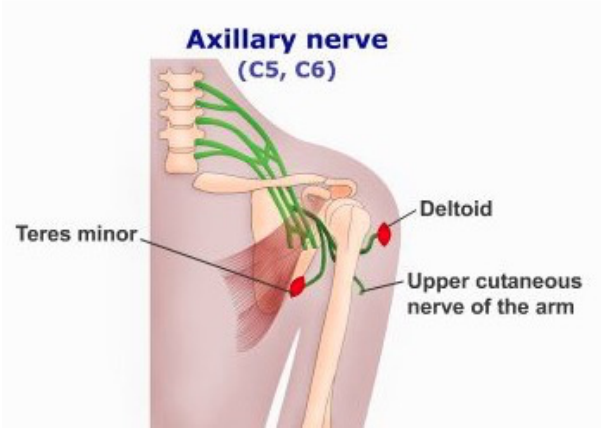

  - Motor
    - Teres minor (ext rotation shoulder)
    - Deltoids
  - Injury:
    - Regimental patch
    - Runs posterior around humerus

        - shoulder dislocation, fractured humeral neck —> cutaneous sensation, deltoid and teres minor muscles affected
- **Median**
    - From lateral and medial cords of plexus
        - 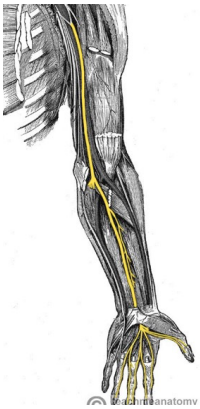
        - Starts lateral —> then medial to brachial artery
    - **<u>BRANCHES (5 total):</u>**
        1. **Median nerve**
            1. Pronator teres
            2. FDS
            3. Palmaris longus
            4. Flexor carpi radialis
        2. **Anterior interosseous nerve** -
            - FDP
            - Flexor pollicis longus
            - Pronator quadratus
            - 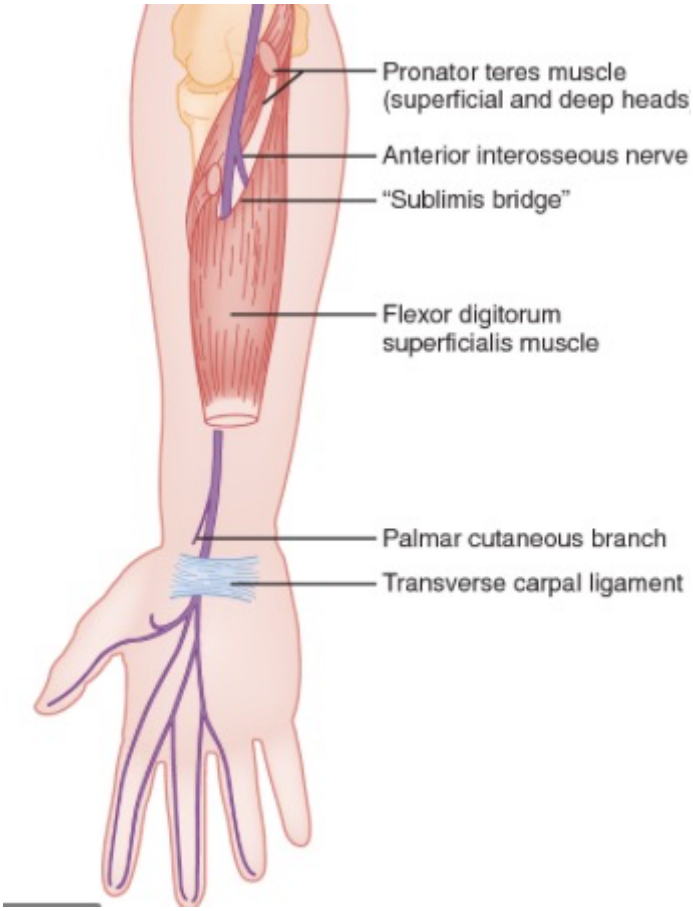

        3. **Recurrent branch -** thenar muscles (except adductor policies longus)

        - Abductor pollicis brevis
        - Flexor pollicis brevis
        - Opponens pollicis
    4. **Palmar digital branch**
        - Two lateral lumbricals (index and middle fingers)
        - Palmar surface and lateral 3 digits cutaneous
    5. **Palmar cutaneous -** skin of the lateral palm
        - 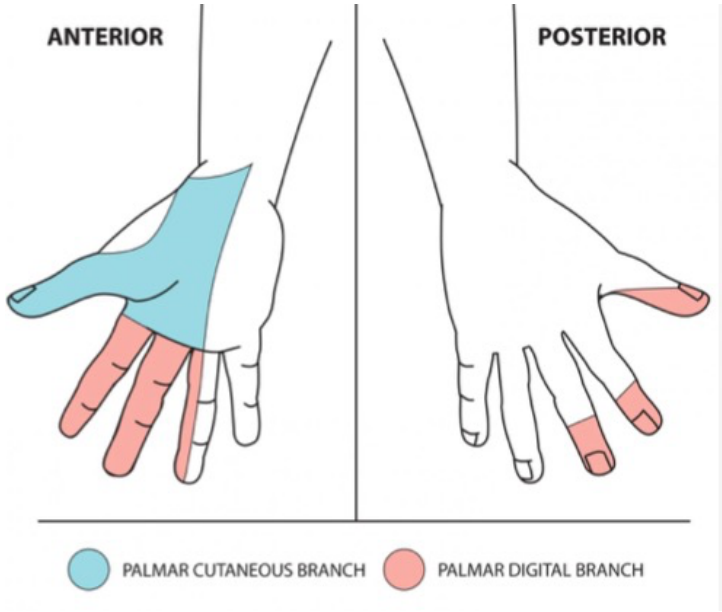

    - Injury/lesion
        - Risk of injury in *supracondylar fractures:*
            - 
        - *At elbow:*
            - Thenar wasting
            - Hand of Benediction (when trying to make a fist only 4th and 5th fingers flex)
            - Unable to **abduct thumb (point to ceiling) -** abductor pollicis brevis
        - Carpal tunnel syndrome, can also —> thenar wasting
- **Radial**
    - <u>COURSE:</u>
        1. 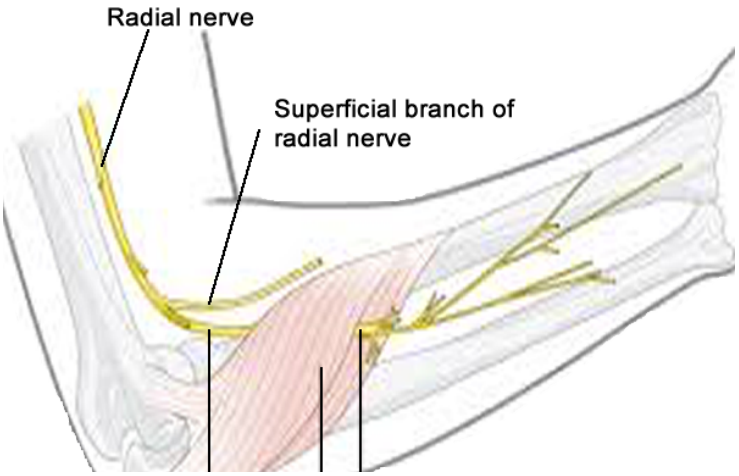



2. Radial groove posterior to proximal humerus
3. Then wraps around laterally --> and accompanies brachial artery down humerus
4. Travels anteriorly over lateral condyle humerus into ACF
   - At ACF (before supinator) radial nerve bifurcates:
     - 1. --> superficial branch Radial n (SENSORY dorsal hand and fingers)
     - 2. --> deep branch radial n (MOTOR)
       - When deep branch passes through the supinator muscle, it then is called POSTERIOR INTERROSEOUS N for rest of its course
- **Motor**
  - Triceps
  - Bracioradialis and supinator = **forearm supinators**
  - Forearm posterior compartment
  - Abductor pollicis longus
- **Sensation**
  - mollytim
  -
- Injury/lesion
  - Axilla - wrist drop and ↓ elbow extension
  - Radial groove (e.g. humeral shaft fracture) - wrist drop and grip weakness
    - *saturday night palsy*

- **Ulnar**
  - 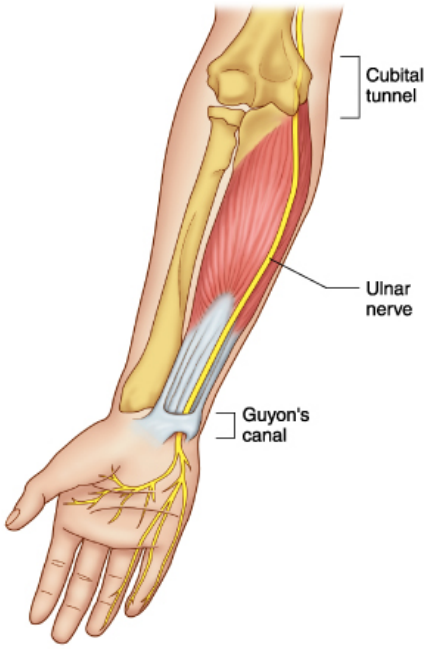

  - Posterior to medial epicondyl. Follows ulnar artery in forearm.
  -

Branch	Muscles supplied
Muscular branches of the ulnar nerve	Flexor carpi ulnaris

(in the forearm)	Flexor digitorum profundus (medial ½)
The deep branch of the ulnar nerve (in the hand)	Hypothenar muscles • Opponens digiti minimi • Abductor digiti minimi • Flexor digiti minimi brevis 3rd and 4th lumbricals Dorsal interossei Palmar interossei Adductor pollicis Flexor pollicis brevis (deep head)
The superficial branch of the ulnar nerve (in the hand)	Palmaris brevis

- **Sensory**
  - 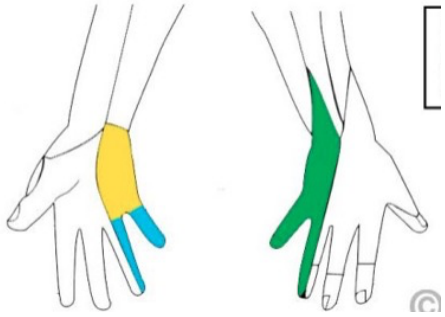
  - YELLOW - palmar cutaneous branch
  - BLUE - superficial branch
  - GREEN - dorsal cutaneous branch
- **Motor**
  1. Flexor carpi ulnaris
  2. Median half of flexor digitorum profundus (two tendons to little and ring fingers)
  3. Two distal branches:
     - Superficial branch ulnar n: sensation medial 1.5 fingers
     - Deep branch ulnar n: (**hand muscles**)
       - Median two lumbricals, all interossei, hypothenar muscles
       - Only innervates adductor policis longus for thenar muscles (the rest are innervated by median nerve)
- **Injury/lesion**
  - <u>Proximal</u>
    - Weakness of wrist flexion = *flexor carpi ulnaris*
    - Claw hand = *medial two lumbricalls*
    - Weakness abduction/adduction of fingers = *interossei*
    - Weakness DIPJ of little and ring finger = *flexor digitorum profundus*
    - Weakness abduction and opposition of little finger = *hypothenar muscles*
    - Froment's sign = *adductor policis*
    - Median half palm sensory loss
    - Hypothenar wasting
  - <u>Distal</u>
    - Intrinsic hand muscles affected only
      - Claw hand = *medial two lumbricalls*

        - Weakness abduction/adduction of fingers = *interossei*
        - Weakness abduction and opposition of little finger = *hypothenar muscles*
    - Notes:
        - **Ulnar nerve paradox**
            - More severe clawing paradoxically occurs with distal lesions and this is a favourite exam question. The reason for this is that in proximal lesions the ulnar supply to FDP is lost and as FDP causes finger flexion its paralysis means the fingers can extend. In distal lesions FDP remains innervated and is able to contract causing flexion which exacerbates the clawing.
        - Hold paper between finger = interossei muscles (palmar)
        - Claw hand
            - Paralysed median two lumbricals
            - Unopposed extension at MCPJs, unopposed flexion at IPJs
        - Froment's sign - flexion at IPJ to hold paper, unable to adduct thumb
            - Adductor policis not working (thumb adduction)
            - 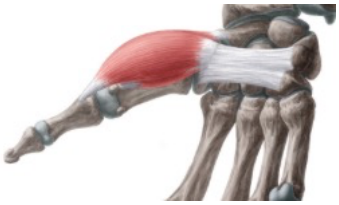

              APB
            - 

            - Uses flexor pollicis longus (median nerve)

Brachial nerve Injuries

- Upper plexus injury (Erb's palsy)
    - Due to excessive angle of neck and shoulder - shear/tear upper nerve roots
    - C5/C6
    - Erb's palsy - waiter's tip position
        - High speed trauma / shoulder dystocia at birth etc
        - Supraspinatus, infraspinatus, trapezius, deltoids, biceps, coracobrachialis, brachialis
        - 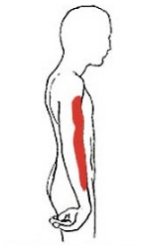
        - **Can't adduct shoulder or flex arm** - Medially rotated (unopposed pec muscles), extended (no elbow flexors), flexed wrist (increased flexor tone relative to extensors)

- Lower plexus injury (Klumpke Palsy)
  - Excessive abduction - e.g. catching branch as falling, pulling kid up by arm
  - C8/T1 root
  - 

    claw hand
  - Unopposed action of finger extensor muscles. Lumbricals normally flex MCPJs and extend IPJs —> paralysis of these will do the opposite.

	Ulnar Claw	Hand of Benediction
Nerve Involved	Lesion of ulnar nerve at the wrist.	Lesion of the median nerve at the elbow or at the wrist.
Typical Presentation	Appears in long standing cases.	Appears when patient attempts to make a fist.
Digits Affected	Little and ring.	Middle and index.
Muscles Paralysed	• Medial two lumbricals	• Lateral two lumbricals • Lateral half of the FDP
Movements involved	Unopposed extension at the MCP Joints Unopposed flexion at the IP joints	***Inability*** to flex at the MCP and IP joints of the middle and index fingers ***Voluntary*** flexion at the MCP and IP joints of the ring and little fingers

REFLEXES root values

- Biceps: C5-C6
- Triceps: C7-C8
- Finger: C8

Sensory

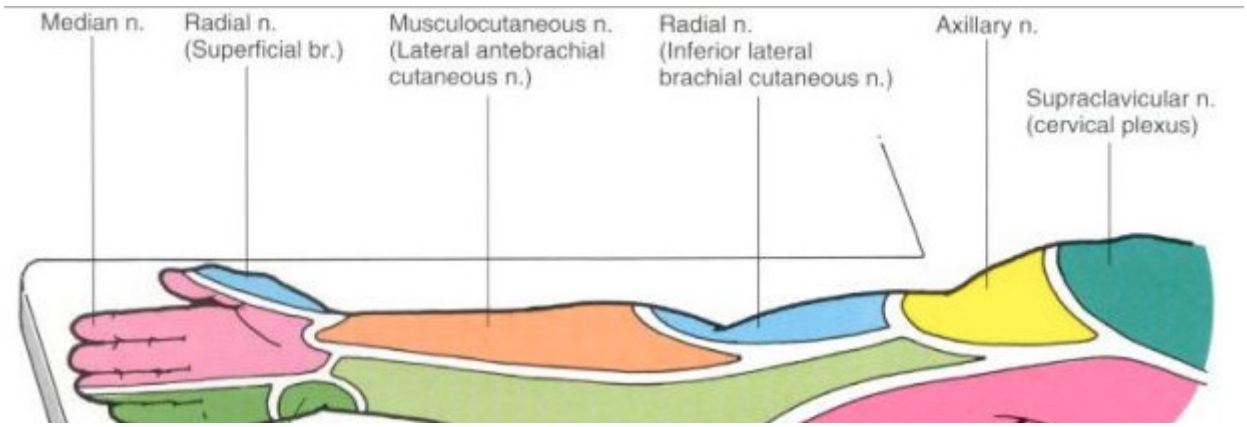

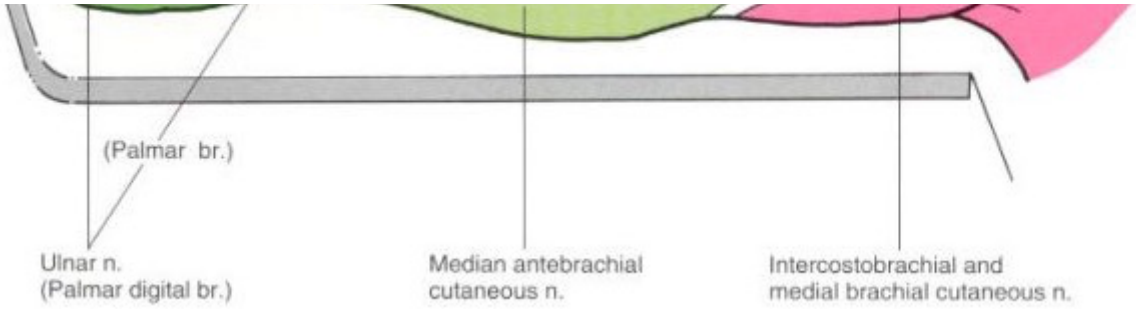
(Palmar br.)
Ulnar n.
(Palmar digital br.)
Median antebrachial
cutaneous n.
Intercostobrachial and
medial brachial cutaneous n.

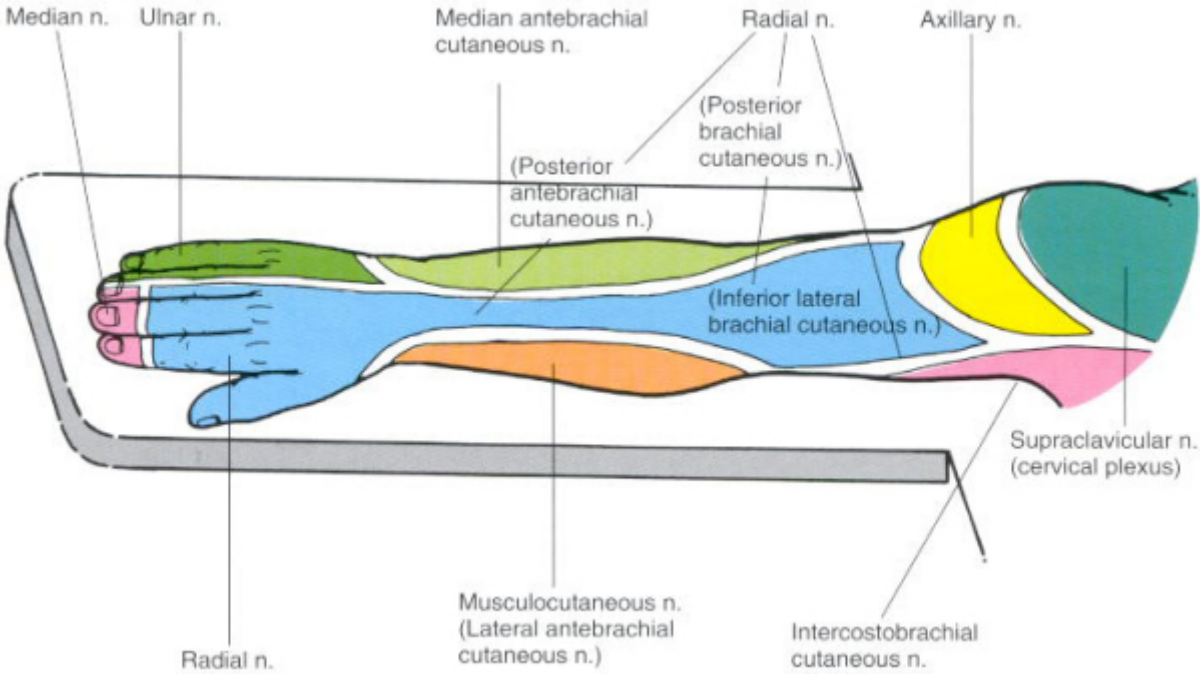
Median n.
Ulnar n.
Median antebrachial
cutaneous n.
Radial n.
Axillary n.
(Posterior
brachial
cutaneous n.)
(Posterior
antebrachial
cutaneous n.)
(Inferior lateral
brachial cutaneous n.)
Supraclavicular n.
(cervical plexus)
Musculocutaneous n.
(Lateral antebrachial
cutaneous n.)
Intercostobrachial
cutaneous n.
Radial n.

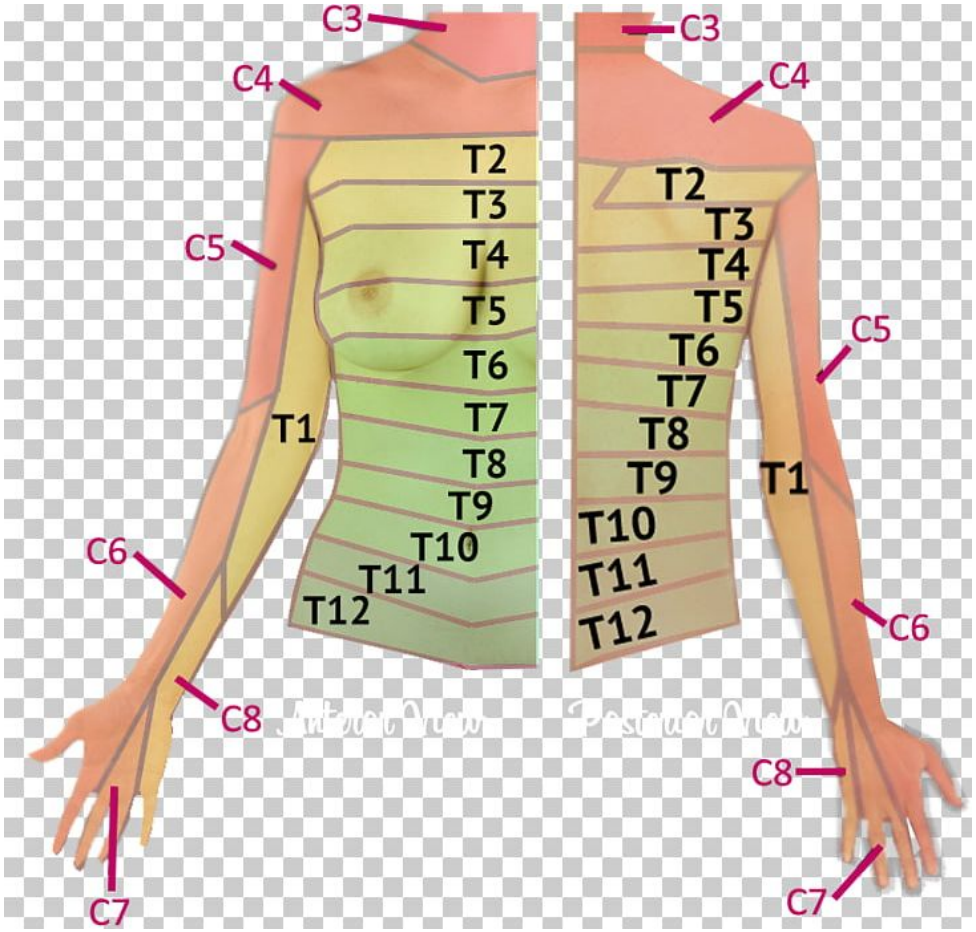
C3
C4
C5
C6
C8
C7
T1
T2
T3
T4
T5
T6
T7
T8
T9
T10
T11
T12
Anterior View
Posterior View

Table: Dermatomal Supply of the Upper Limb

Dermatome	Landmark
C2	Occipital Protuberance
C3	Supraclavicular Fossa
C4	Acromioclavicular Joint
C5	Lateral Antecubital Fossa
C6	Thumb
C7	Middle Finger
C8	Little Finger
T1	Medial Antecubital Fossa
T2	Apex of Axilla

Brachial artery

- From axillary artery, terminates into radial and ulnar arteries below elbow
- Brachial a —>
  - Profunda/deep brachial (posterior compartment of arm)
  - Muscular
  - Nutrient artery
  - Ulnar (sup and inf) collaterals
  - Common interosseous artery (at around radial tuberosity) —> divides into ant and post interosseous artery either side of the interosseous ligament
  - Terminal (ulnar and radial) arteries
    - 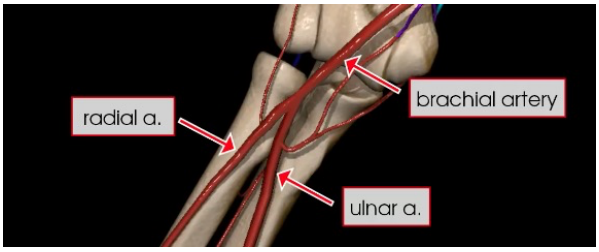

- Venae comitantes
  - The deep veins that accompany the large arteries (brachial, radial, ulnar)

Ulnar nerve	Median nerve	Ulnar artery

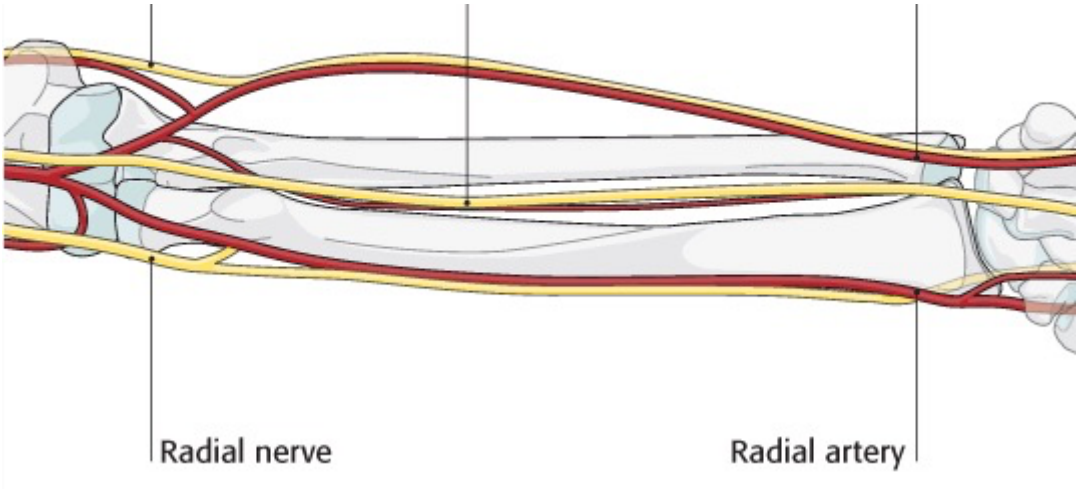

Radial and ulnar arteries join together

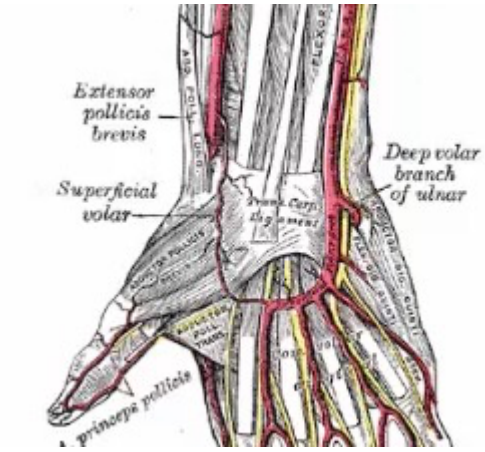

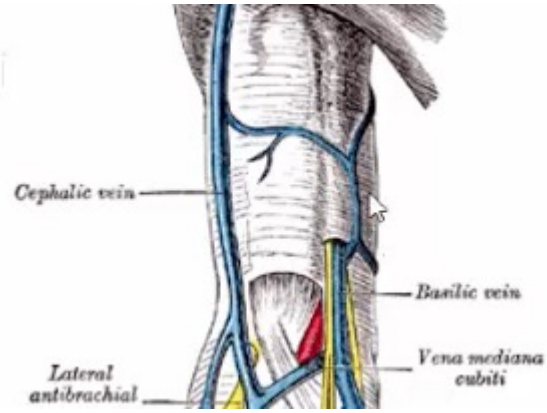

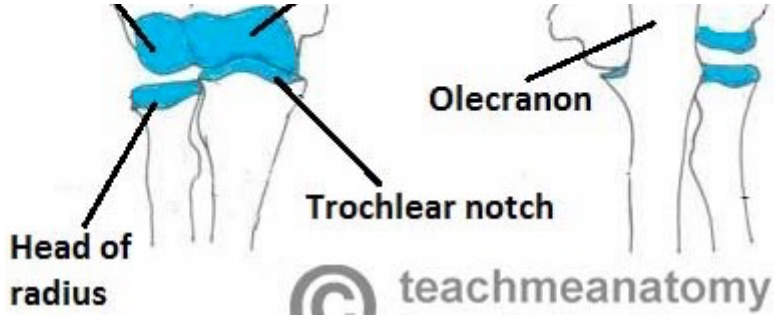

Ligaments (3)

- Radial/lateral collateral - from lateral epicondyle to radial aspect of annular lig
- Ulnar/medial collateral - from medial epicondyle to olecranon of ulna and coronoid process (two ligaments):
  - Radial collateral
  - Lateral ulnar collateral (lat epicondyle to ulna)
- Annular (radio-ulnar)

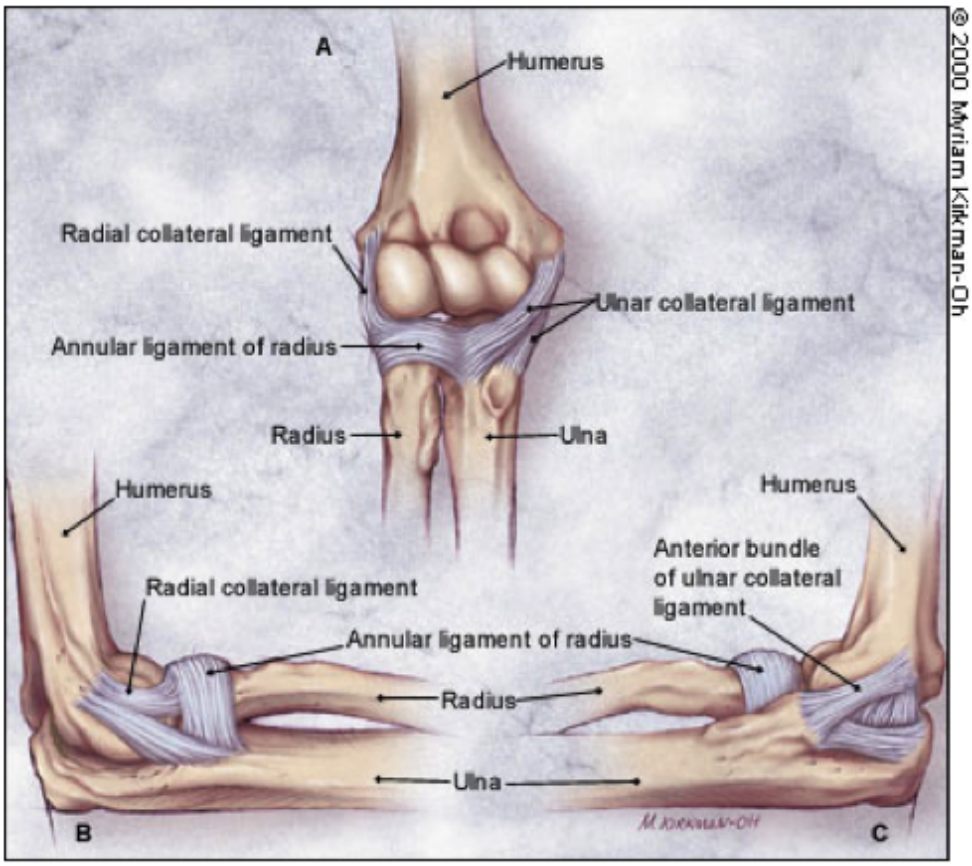

Formation of epiphyses in kids

To be able to distinguish epiphyses from fractures

C capitellum
R radial
I internal epicondyle
T trochlear
O olecranon
L lateral epicondyle

Each forms roughly 2 yrs apart
Eg 1yo capitellum, 3yo radial etc
nb internal = medial epicondyle

FOREARMS

Supination - brachioradialis, biceps brachii, supinator
Pronation - pronator teres, pronator quadratura

(8) Flexor muscles (flexors and pronators)

- Anterior (*wrist flexors)*
  - Pronator teres
  - Flexor carpi radialis (attach to pisiform)
  - Palmaris longus (absent in 15% people)
  - Flexor carpi ulnaris (attach to base of MCPs medial)
- Middle *(flexes MCPJs and PIPJs)*
  - Flexor digitorum superficialis
- Deep **(deep innervated by anterior interroseous nerve (branch of median))**
  - Flexor digitorum profundus - *flexes DIPJs*
  - Flexor policis longus
  - Pronator quadratus

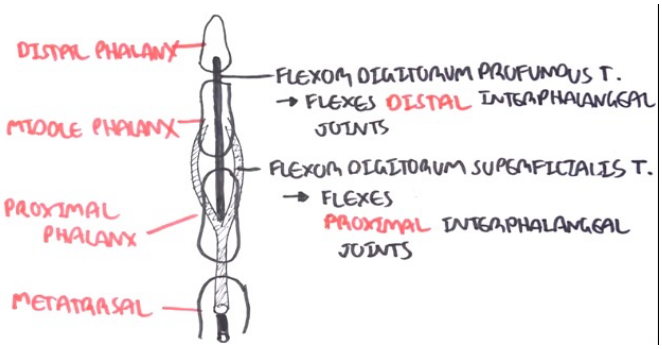

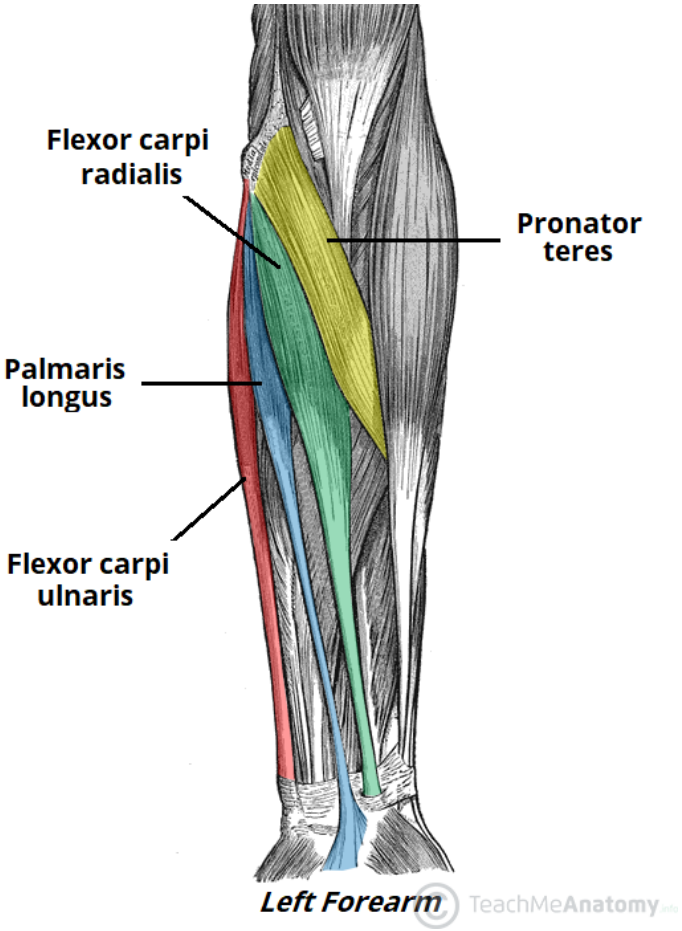

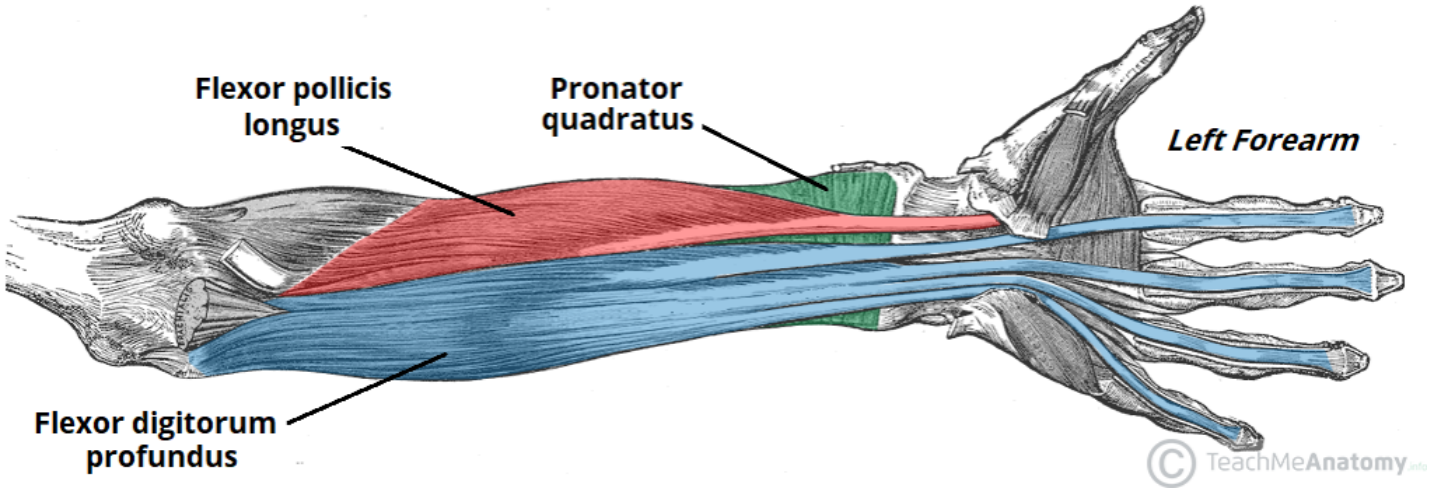

Table: Digital Attachments of the Long Flexor Tendons

Flexor Tendon	Distal Attachment
Flexor pollicis longus	Base of distal phalanx of thumb
Flexor digitorum profundus	Distal phalanges of all four digits
Flexor digitorum superficialis	Middle phalanges of all four digits
Flexor carpi ulnaris	Pisiform, hook of hamate and 5th metacarpal

Flexor carpi radialis	Base of 2nd and 3rd metacarpal
Palmaris longus	Palmar aponeurosis

---

(12) Forearm extensors (extensors, supinators, and abductors)

Common origin is lateral epicondyle —> pass through extensor retinaculum at wrist

All radial nerve

- Superficial
  1. Brachioradialis (ext and supinator) (originates humerus)
  2. Extensor carpi radialis longus
  3. Extensor carpi radialis brevis
  4. Extensor digitorum (to all 4 fingers (excl thumb))
  5. Extensor digiti minimi (to little finger)
  6. Extensor carpi ulnaris
  7. Anconeus - weak elbow extensor
- Deep
  1. Supinator
  2. Abductor pollicis longus
  3. Extensor pollicis longus
  4. Extensor pollicis brevis
  5. Extensor indicis (index finger)

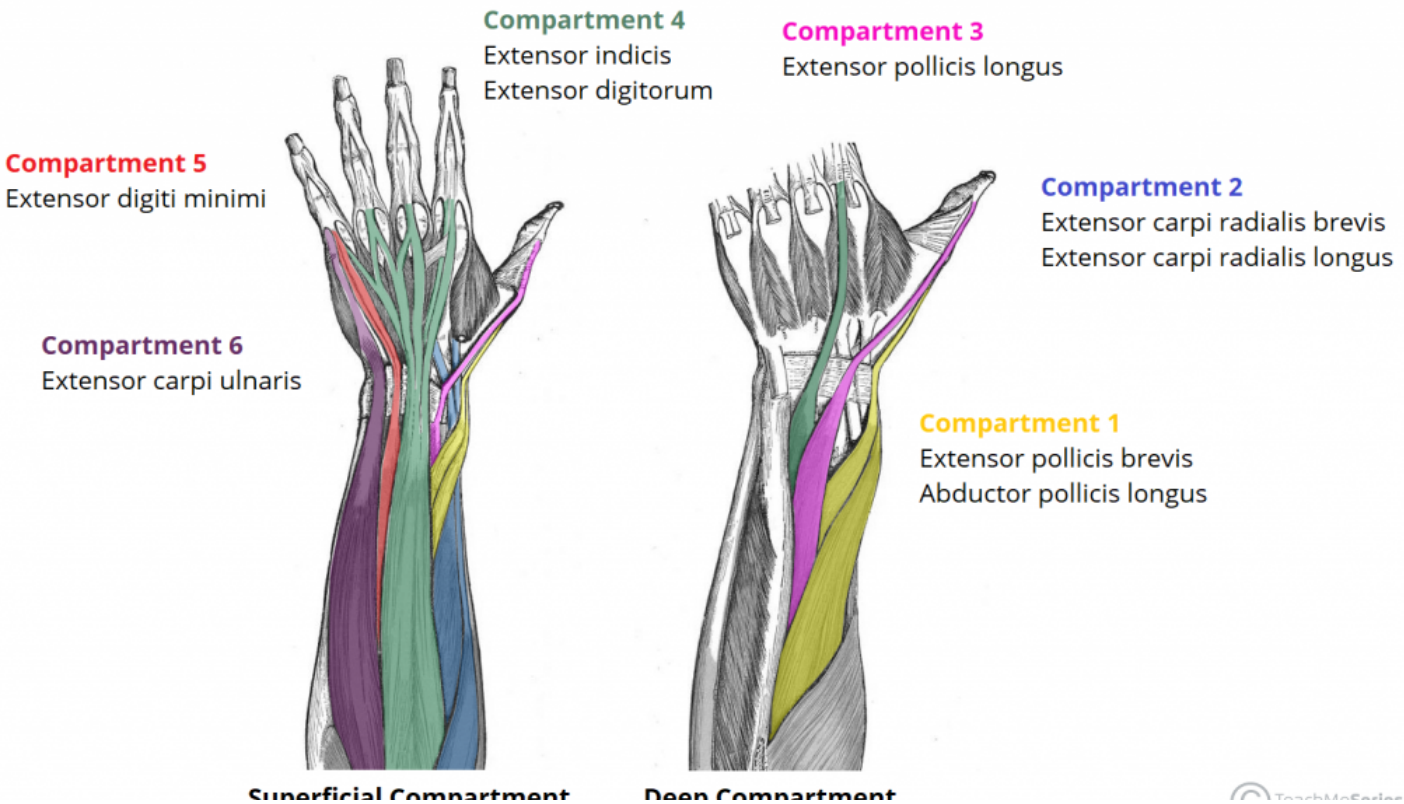

Superficial compartment Deep compartment

ANATOMICAL SNUFF BOX

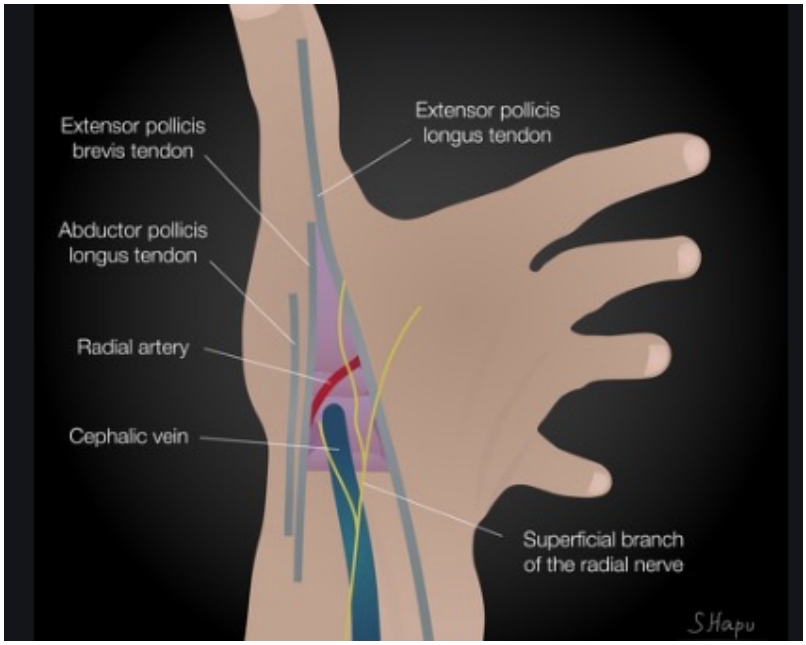

- Formed by borders of extensor pollicis longus and brevis
- Can palpate trapezium and scaphoid bone within
- Radial nerve sensory terminal branches runs through
- Radial artery on floor

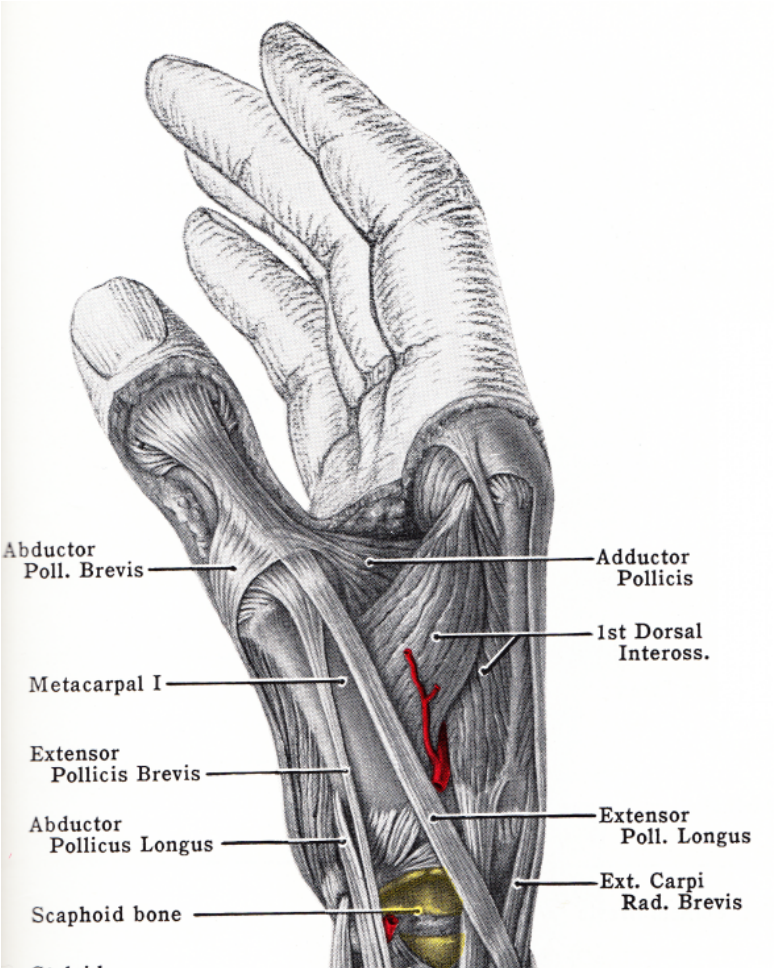

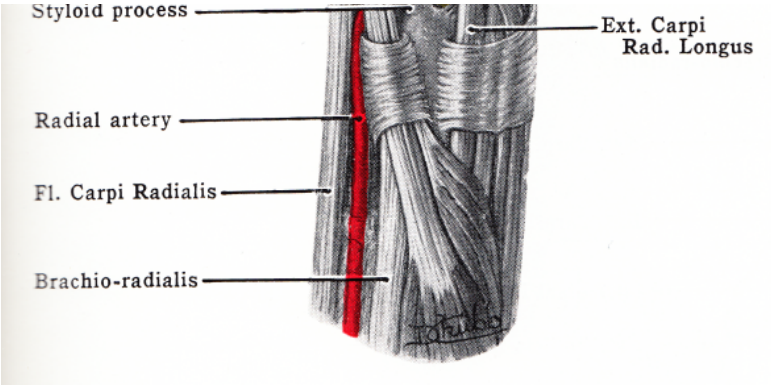

NOTE WHERE BONES ARE IN THE ANATOMICAL SNUFFBOX

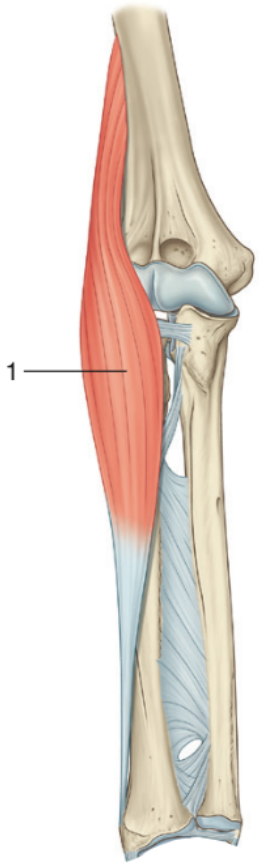

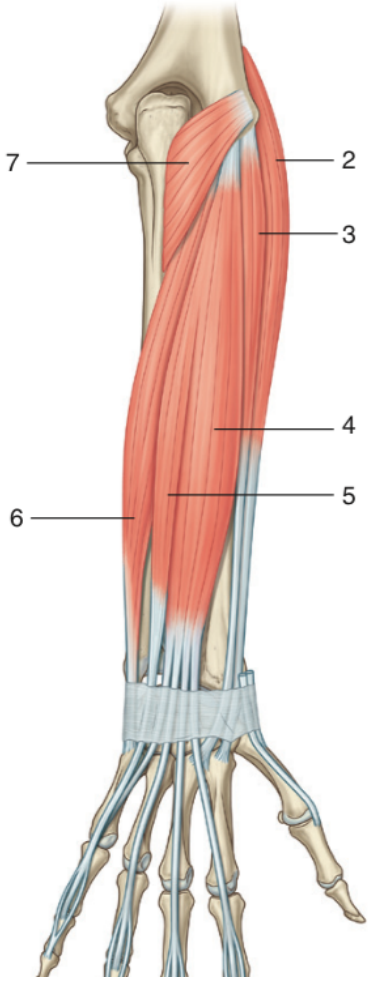

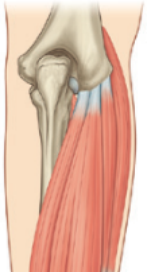

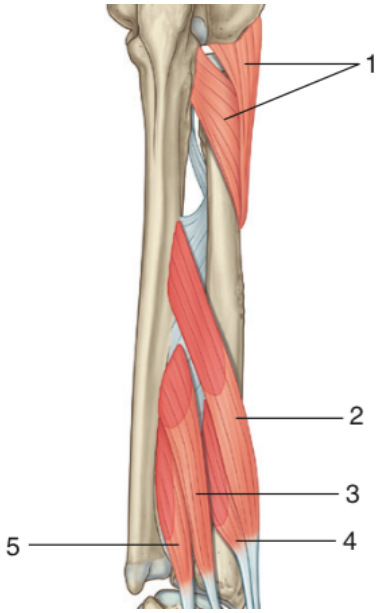

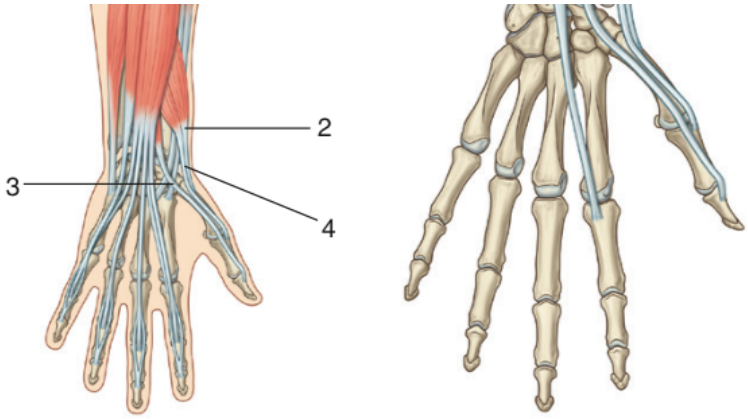

Table: Digital Attachments of the Long Extensor Tendons

Muscle Tendon	Distal Attachment
Extensor carpi radialis longus	Dorsal surface of base of 2nd metacarpal
Extensor carpi radialis brevis	Dorsal surface of base of 2nd and 3rd metacarpal
Extensor digitorum	Dorsal aspects of bases of middle and distal phalanges of index, middle, ring and little fingers via extensor hoods
Extensor carpi ulnaris	Tubercle on base of 5th metacarpal
Abductor pollicis longus	Lateral side of base of 1st metacarpal
Extensor pollicis longus	Dorsal surface of base of distal phalanx of thumb
Extensor pollicis brevis	Dorsal surface of base of proximal phalanx of thumb
Extensor indicis	Extensor hood of index finger
Extensor digiti minimi	Extensor hood of little finger

HAND

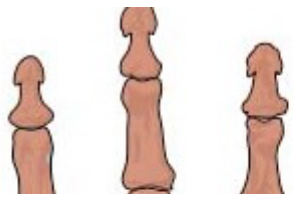

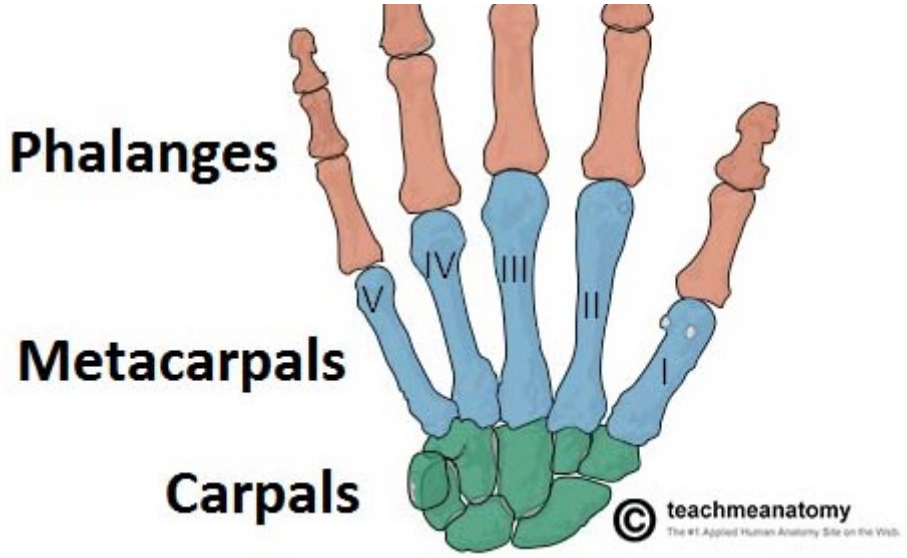

Flexion – Produced mainly by the flexor carpi ulnaris, flexor carpi radialis, with assistance from the flexor digitorum superficialis.

Extension – Produced mainly by the extensor carpi radialis longus and brevis, and extensor carpi ulnaris, with assistance from the extensor digitorum.

Adduction – Produced by the extensor carpi ulnaris and flexor carpi ulnaris

Abduction – Produced by the abductor pollicis longus, flexor carpi radialis, extensor carpi radialis longus and brevis.

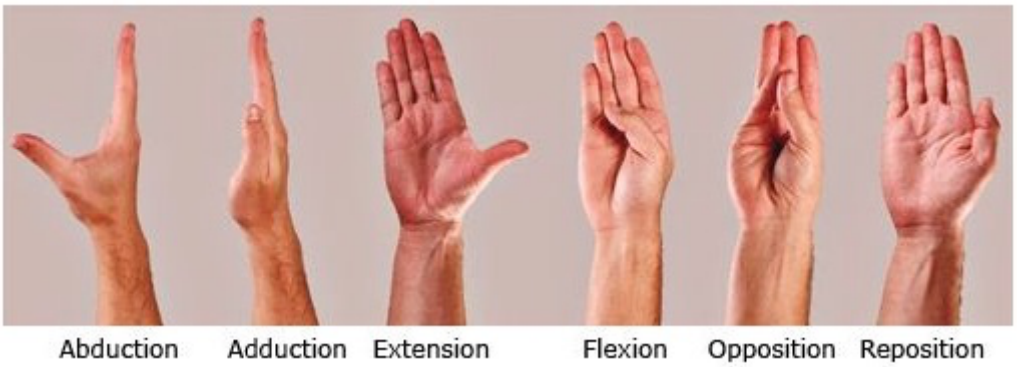

Carpal bones: Some lovers try positions that they can't handle

Dupytren's contracture:

- Localised thickening of palmar aponeurosis

Trigger finger

- Localised tendon thickening of flexor tendon
- 

FLEXOR TENDON NODULE

CARPAL TUNNEL

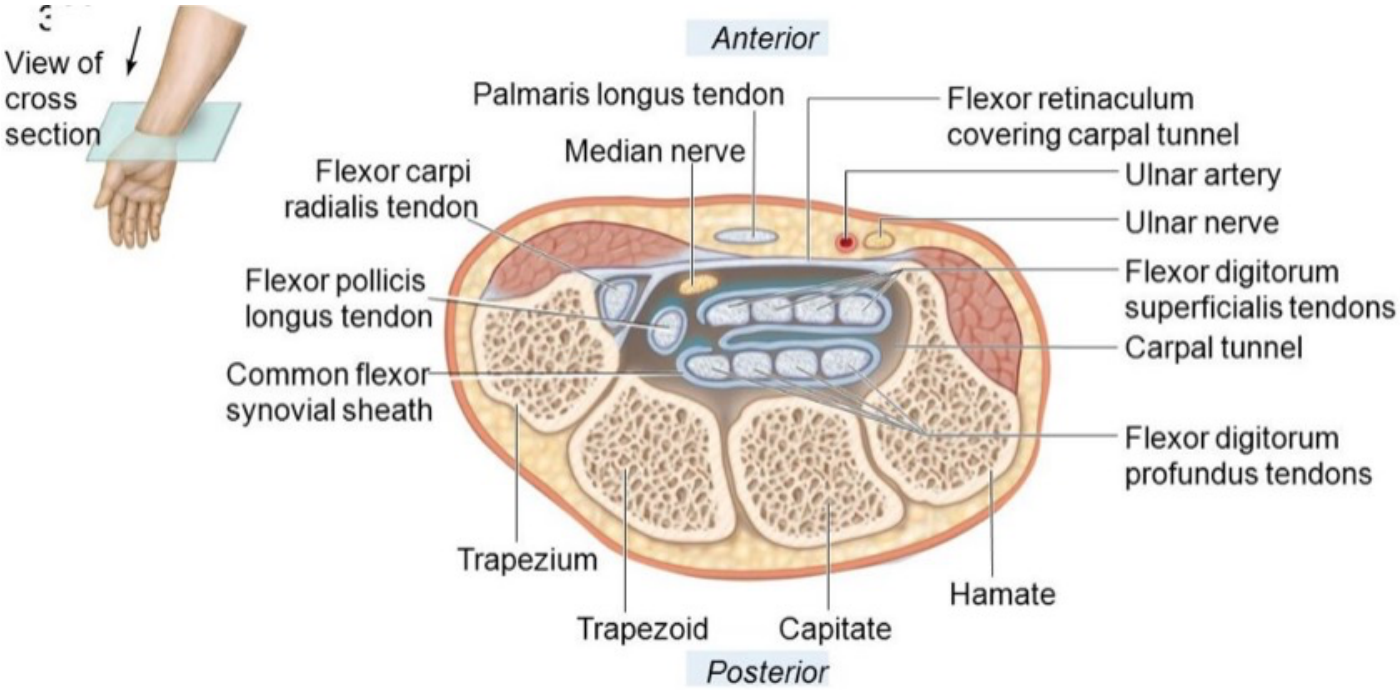

- Contains:
  - Flexor digitorum superficialis tendons (4)
  - Flexor digitorum profundus tendons (4)
  - Flexor pollicis longus tendon
  - Median nerve
- Borders:
  - Ant: flexor retinaculum - crosses hamate/pisiform to trapezium/scaphoid
  - Lateral: trapezium
  - Medial: hamate
  - Floor: trapezoid and capitate
- Sx
  - Median distal nerve distribution sensory loss/paraesthesia
  - In bad cases may have motor disturbance
  - *Note: superficial/palmar cutaneous branch of median nerve diverges before tunnel and runs superficial to it. Will have preserved palmar sensation*
    - 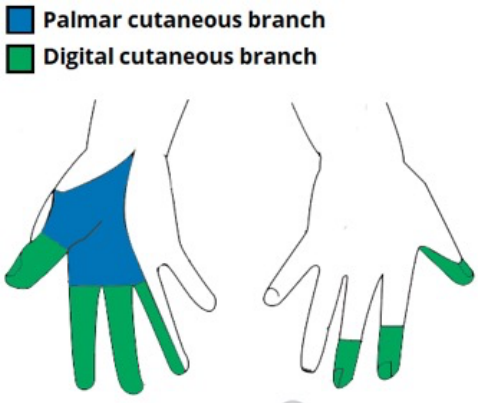

Flexor retinaculum:

- Passing above:
  - Palmaris longus
  - Ulnar artery
  - Ulnar nerve
- Passing below: contents of carpal tunnel

Flexor tendon sheaths

Clinical significance = if infection in distal part of finger, infection can —> track into palm down sheaths

There are also flexor and extensor retinaculums, on anterior and posterior of wrist

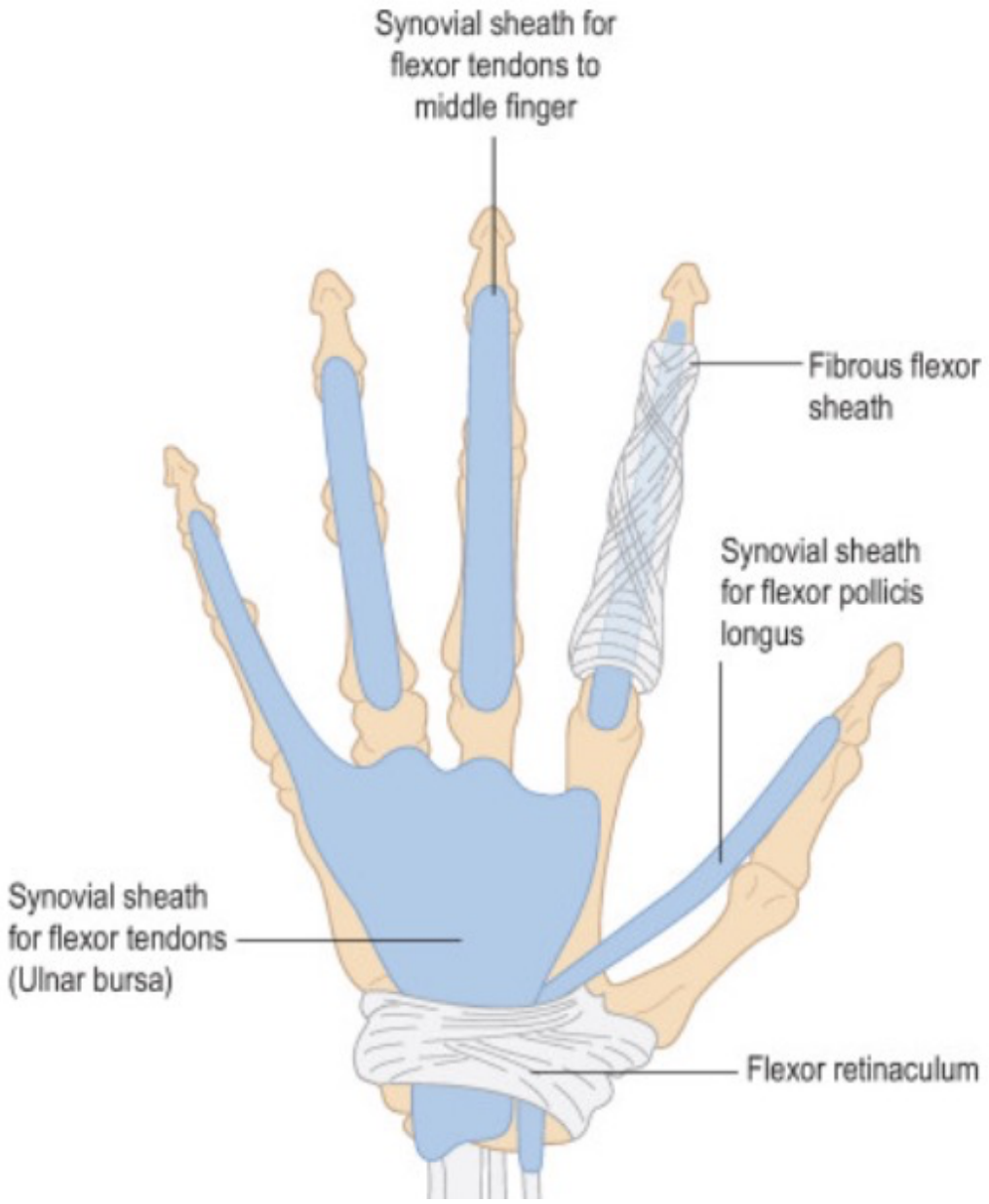

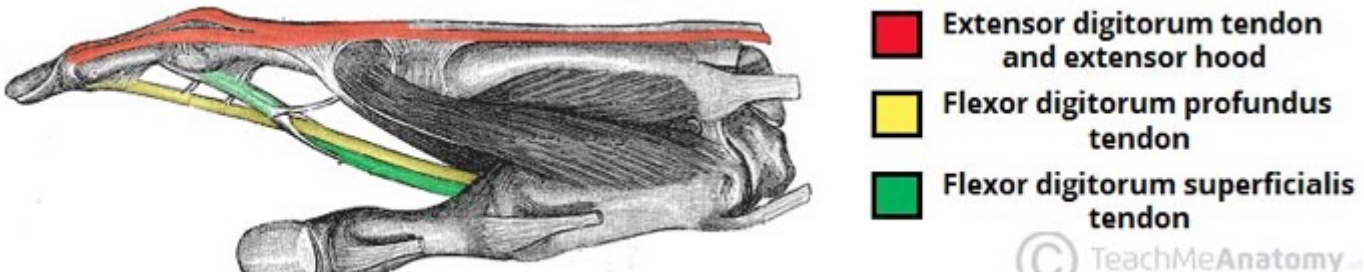

Mallet finger

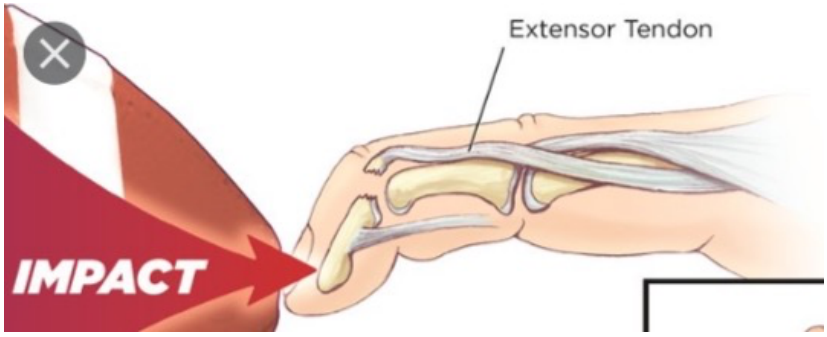

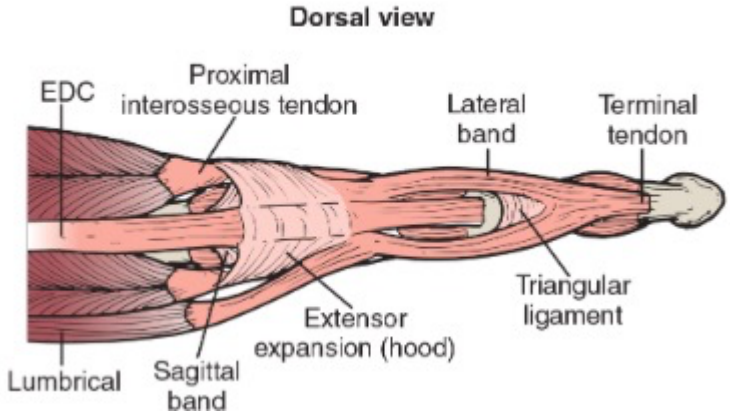

<u>HAND MUSCLES</u>

1. Thenar - originate from flexor retinaculum - ***recurrent branch of medial nerve innervates***
    1. Opponens pollicis
    2. Flexor pollicis brevis
    3. Abductor pollicis brevis
2. Adductor pollicis (ulnar n)
    1. 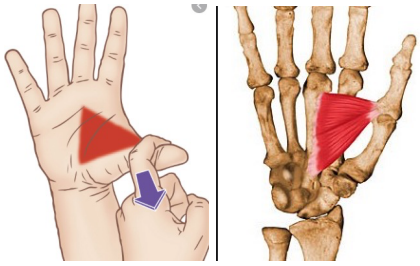
3. Hypothenar - originate from flexor retinaculum
    1. Opponens digiti minimi
    2. Flexor digiti minimi brevis
    3. Abductor digiti minimi
4. Lumbricals
5. Interossei

Thenar muscles (coloured in)

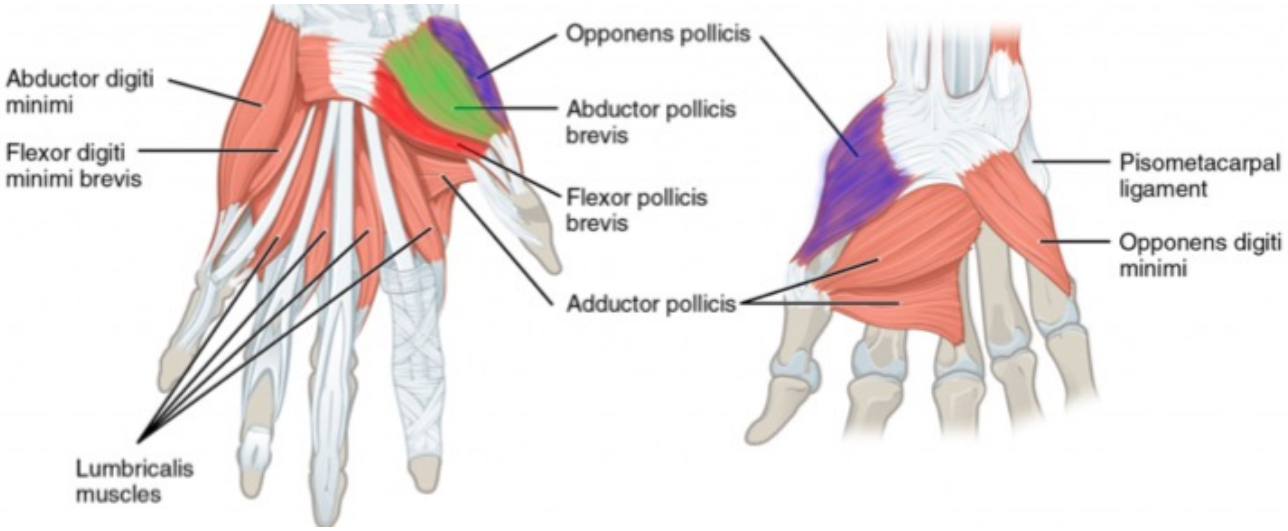

Table: Movements of the Finger Joints

Finger Movements	Primary Muscle (Assisting Muscles)
Flexion of MCPJ of digits 2 – 5	Lumbricals (flexor digitorum superficialis, flexor digitorum profundus, flexor digiti minimi, interossei)
Flexion of PIPJ of digits 2 – 5	Flexor digitorum superficialis (flexor digitorum profundus)
Flexion of DIPJ of digits 2 – 5	Flexor digitorum profundus
Extension of MCPJ of digits 2 – 5	Extensor digitorum, extensor indicis, extensor digiti minimi
Extension of PIPJ and DIPJ of digits 2 – 5	Lumbricals and interossei (extensor digitorum)
Adduction of digits 2 – 5	Palmar interossei
Abduction of digits 2 – 4	Dorsal interossei
Abduction of little finger	Abductor digiti minimi
Opposition of little finger	Opponens digiti minimi

Thenar Eminence

Muscle	Innervation	Action
Abductor Pollicis Brevis	• Median Nerve C8/T1	Abduction & Opposition

Flexor Pollicis Brevis	• Median C8/T1 & deep Ulnar Nerve	Flexion at MCPJ
Opponens Pollicis	• Median Nerve	Opposition of thumb

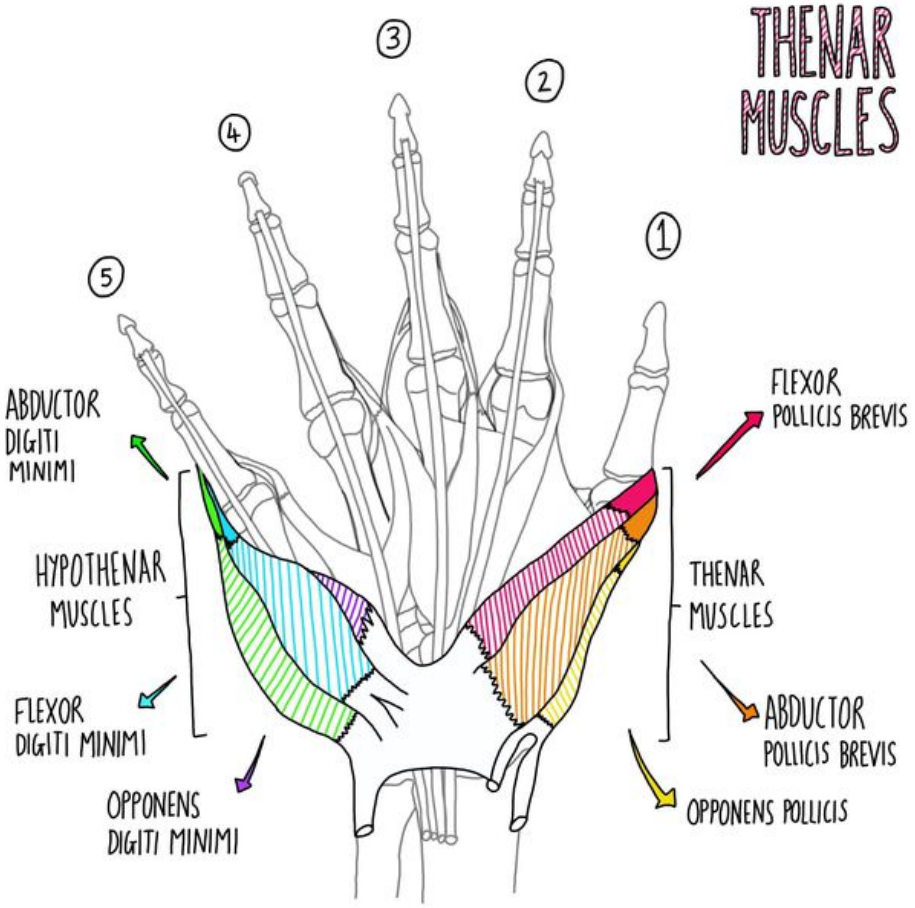

Remember

- Ulnar artery -> superficial arch
- Radial artery -> deep arch

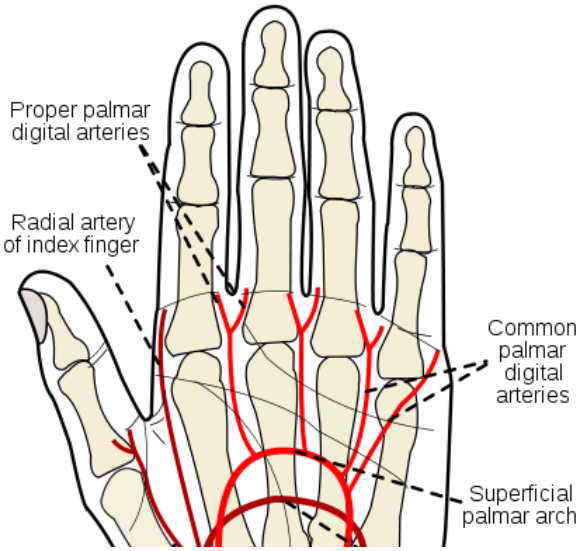

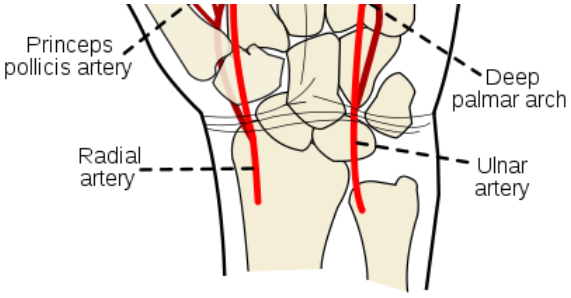

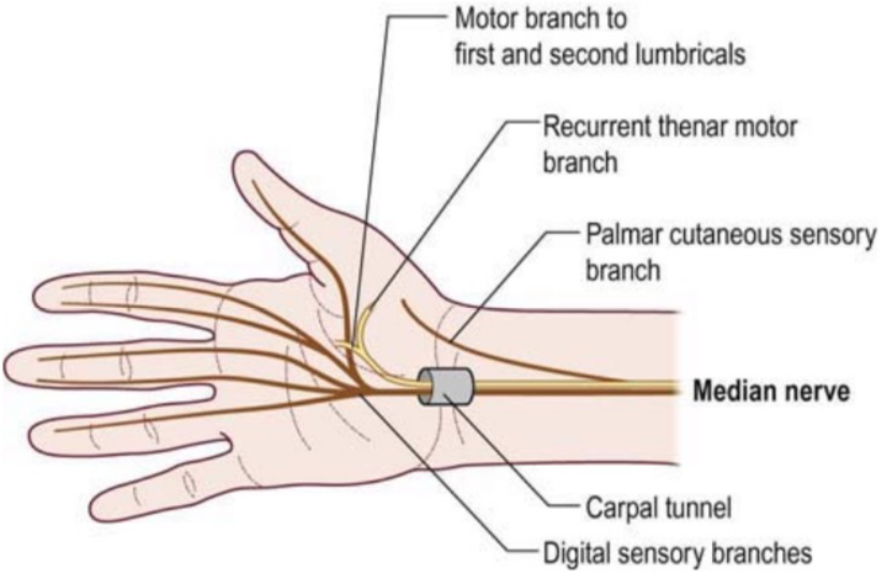

Median n. - lateral two lumbricals and thenar muscles
Ulnar n. - interossei, other lumbricals, and hypothenar

- Ulnar n. passes through Guyon's canal on palmar side.
- Ulnar artery also passes through
- 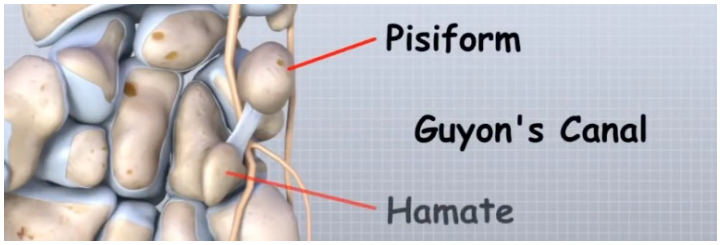

Lumbricals

- Origin - **palmar -** radial side of tendons of FDP muscle
  - 
- Insertion - **Dorsal -** extensor expansion
  - 

MCPJ flexion and PIPJ + DIPJ extension - because the muscle crosses from palmar to dorsal extensor tendons
Arise from flexor digitorum profundus tendons